

The use of intra-articular anesthesia as a diagnostic tool in canine lameness

Het nut van intra-articulaire anesthesie als diagnosemiddel voor manken bij de hond

D. Van Vynckt, Y. Samoy, L. Mosselmans, G. Verhoeven, F. Verschooten, B. Van Ryssen

Department of Medical Imaging and Small Animal Orthopedics
Faculty of Veterinary Medicine, Ghent University,
Salisburylaan 133, B-9820 Merelbeke, Belgium

delphine.vanvynckt@ugent.be

ABSTRACT

Lameness in dogs may be difficult to localize because of mild pathologic changes or inconclusive clinical findings. Intra-articular anesthesia is proposed as a diagnostic method to localize the source of lameness. After a description of the preparation, technique and puncture sites, an overview is given of a series of patients admitted for different joint problems. Intra-articular anesthesia proved to be applicable in any joint, provided that the clinician was experienced and the dog was under sedation. In 87% of the cases, intra-articular anesthesia was positive. Medial coronoid disease of the elbow joint was the most frequent indication for intra-articular anesthesia.

SAMENVATTING

Manken bij de hond is soms moeilijk te lokaliseren omwille van weinig uitgesproken pathologische veranderingen of onduidelijke klinische symptomen. Intra-articulaire anesthesie wordt voorgesteld als een diagnostisch middel om het manken te lokaliseren. Na een beschrijving van de voorbereiding, de techniek en de punctieplaatsen, wordt een overzicht gegeven van een reeks patiënten aangeboden met verschillende gewrichtsproblemen. De studie gaf aan dat intra-articulaire anesthesie toepasbaar was in ieder gewricht, zolang de clinicus ervaring had en de honden gesedeerd waren. De intra-articulaire anesthesie was positief in 87% van de gevallen en problemen aan het ellebooggewricht, meer bepaald een losse processus coronoideus, was de grootste indicatie voor intra-articulaire anesthesie.

INTRODUCTION

Lameness examination in the dog is based on the history, inspection and palpation of the dog and consecutive radiographs of the suspected region. In some dogs, it is difficult to determine the localization of the problem because of the absence of palpable changes, or because of an unreliable pain response of the dog. In addition, plain radiography cannot always be used to confirm the localization of the problem in the suspected joint, because the radiographic changes may be mild or even absent.

Intra-articular anesthesia (IA) offers a simple and fast method to identify the painful joint. The joint is punctured under sedation, and after the retrieval of synovial fluid, a local anesthetic is injected. Consecutively, the dog is observed to evaluate the effect on the lameness. Intra-articular anesthesia may temporarily resolve lameness caused by a variety of lesions. Lameness caused by synovitis, cartilage erosions, osteochondral fragments and lesions of intra-articular

ligaments can all be decreased or eliminated by performing a joint block (Van Vynckt et al., 2010).

In contrast to man and horse (Crawford et al., 1998, Verschooten, 1985), diagnostic intra-articular anesthesia has not been described in the dog. The purpose of this study was to describe the technical details, to evaluate the use under clinical conditions and to describe the indications and possibilities of intra-articular anesthesia in the dog by analyzing a large series of patients with different joint disorders.

MATERIAL AND METHODS

During a period of four years, the files of the dogs that received an intra-articular anesthesia were collected and analyzed. All of the dogs were client-owned pets presented with front limb or hind limb lameness. The final diagnosis was based on the clinical and imaging findings, confirmed by arthroscopy or open surgery.

The preparation of the dogs and the approach to the joints were based on data from the literature (Van

Vynckt et al., 2010) and from own experience. An analysis of the injected joints and their final diagnosis were performed to describe the effect of intra-articular anesthesia and the indications of the technique.

Sedation of the dogs

In most of the dogs, sedation was necessary to allow the joint puncture and subsequent injection of the local anesthetic. Two protocols were used: acepromazine (0.01 to 0.02 mg/kg given IV) (Placivet[®], 20 mg/mL, Codifar, Belgium) and methadone (0.1 to 0.2 mg/kg given IV) (Mephenon[®], 10 mg/mL, Denolin, Belgium), or medetomidine (Domitor[®], 1.0 mg/mL, Orion Pharma, Finland, the dosage was calculated based on body surface area and given IV), afterwards antagonized with atipamezole (Antisedan[®], 5.0 mg/mL, Orion Pharma, Finland) given intramuscularly. Both sedation protocols were used based on a previous study, in which it was concluded that in most cases, lameness is not eliminated by sedation, and that subsequent intra-articular anesthesia may be performed and evaluated. However, in 8% of the cases, lameness decreased after sedation, but the difference was only one grade on a scale of 0 to 10 for each sedation protocol. Although the observed variation was minimal, a change in lameness grade after intra-articular anesthesia should be at least two grades on a scale of 0 to 10 in order to be considered as a positive response (Van Vynckt et al., 2011).

Positioning and preparation of the dogs

The animals were placed in lateral recumbency with the affected joint uppermost, except for the elbow in which a medial approach was preferred. The puncture site was clipped and cleaned with a chlorhexidine/povidone-iodine scrub and alcohol.

Puncture sites

Based on data from the literature (Houlton, 1994; Borer, 2006) and the authors' clinical experience, joint punctures were performed according to the described techniques (Figures 1, 2, 3, 4, 5, 6).

Intra-articular injection

The application of sterile gloves, syringes and needles was essential. In most of the cases, a 25 mm, 22-gauge needle and a 2 ml syringe were suitable. A 55 to 75 mm, 22-gauge spinal needle was required for the hip joint in large or obese dogs, and a 25 mm, 24-gauge needle was used for distal joints and for small dogs. The needle and syringe were connected before needle insertion. Synovial fluid was retrieved before injecting the local anesthetic into the joint. Mepivacaine (Scandicaine 2%[®], 20 mg/ml, AstraZeneca, Belgium) was administered at a dosage of 1.5 mg/kg (Van Vynckt et al., 2010). To ensure a correct technique, it was required that the injection of the local anesthetic into the joint space did not cause any resistance. If resistance was encountered, the needle was redirected or slightly withdrawn until minimal resistance was encountered. Once the local anesthetic was injected, the joint was flexed and extended to evenly distribute the anesthetic into the joint.

Interpretation of the effect of intra-articular anesthesia

All of the dogs were videotaped during walking and trotting. During the first five minutes, the dogs were walked continuously. If the lameness did not improve during that period, walks were repeated every five minutes for a maximum of 30 minutes until the lameness eventually improved. The effect of the intra-articular anesthesia was evaluated by two experienced

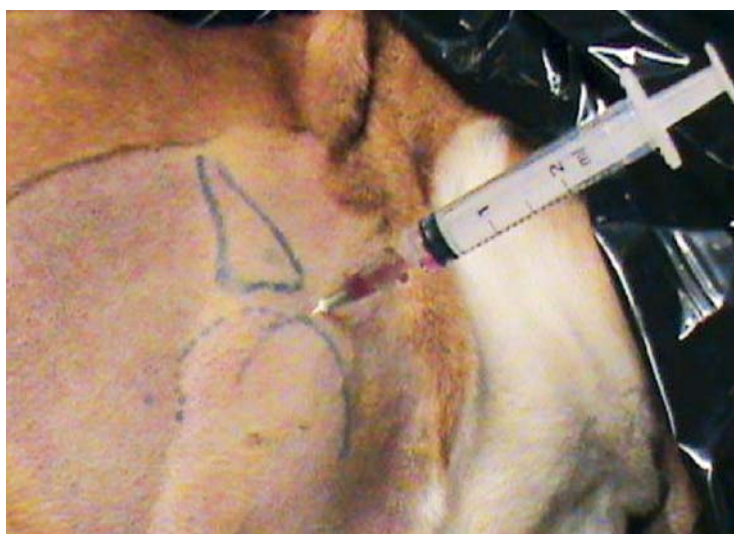
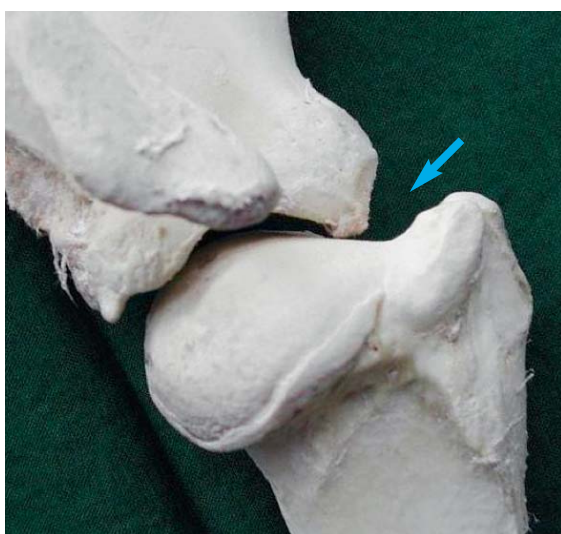
Figure 1. Bony specimen and cadaver specimen of the shoulder joint. The joint is placed in a neutral position and punctured craniolaterally between the acromion and the caudal part of the greater tubercle. The needle is directed caudo-medially and slightly downward. When entering the joint space, a slight decrease of resistance can be noticed.

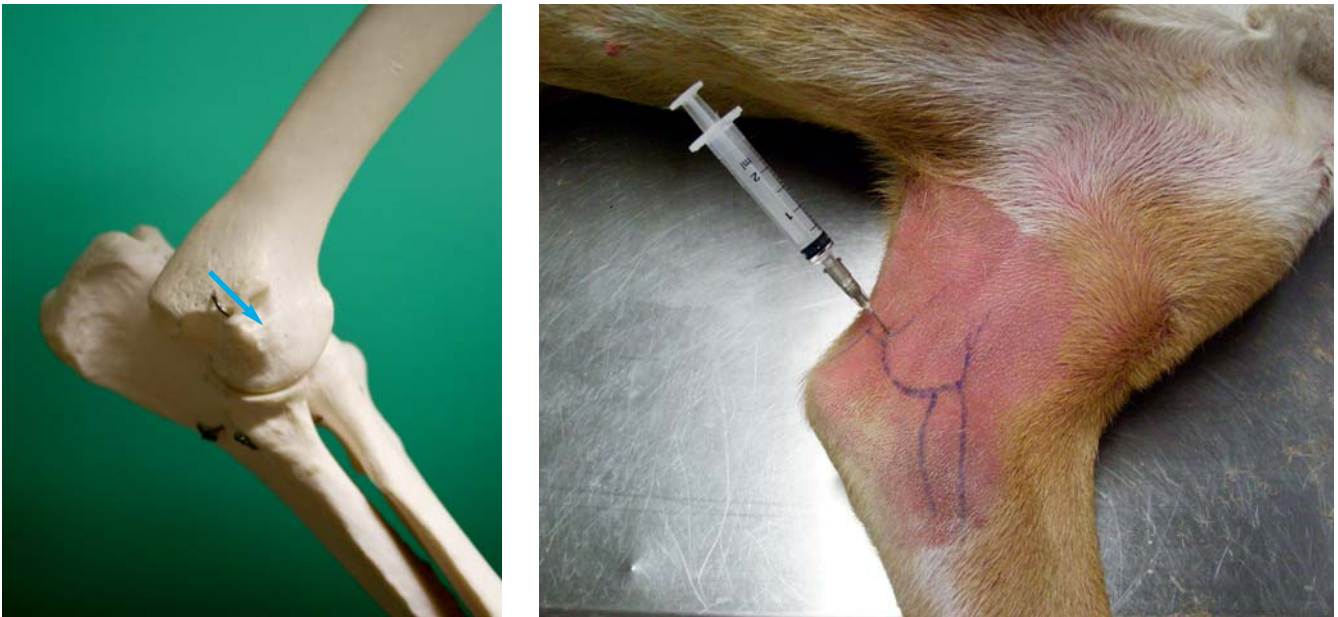


Figure 2. Bony specimen and cadaver specimen of the elbow joint. The dog is placed in lateral recumbency with either the affected limb uppermost or on the table, according to a lateral or medial approach. Lateral injection is chosen for dogs with a deep thorax or excessive skin folds. In both ways, the needle is inserted in the supratrochlear foramen proximal and parallel to the anconeal process.

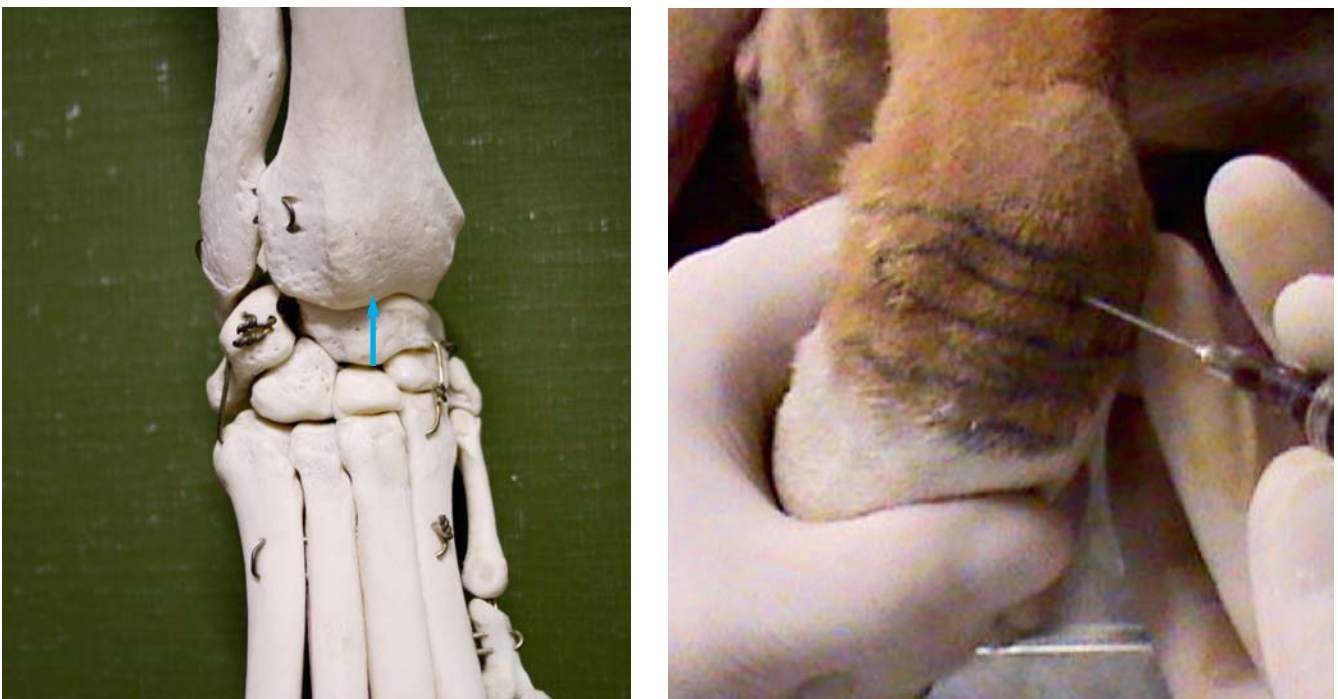


Figure 3. Bony specimen and cadaver specimen of the carpal joint. The antebrachio-carpal joint is the joint most frequently punctured. The carpus is flexed to 90°. A depression, corresponding to the antebrachio-carpal joint space, is palpable distal to the radius. The needle is inserted lateral or medial to the common digital extensor tendon and cephalic vein, which passes over the centre of the dorsal joint space. Injection of the intercarpal and carpometacarpal joints can be performed by flexing the carpus maximally. The intercarpal and carpometacarpal joints communicate with each other, but not with the antebrachio-carpal joint.

clinicians at clinical examination and at a later point in time by scoring the recorded video sequences. The lameness was graded with a numerical rating scale from 0 to 10 (0/10 = sound at all times; 10/10 = continuous non-weight bearing lameness) (Vasseur and Slatter, 1993). Intra-articular anesthesia was considered positive when the lameness improved by at least two

grades on a scale of 0 to 10. The effect was considered negative if the lameness did not improve 30 minutes after the intra-articular anesthesia, or when one of the two observers did not see an improvement of at least two grades. The specificity and sensitivity of the effect of intra-articular anesthesia, as well as the 95% confidence interval of the sensitivity were calculated.

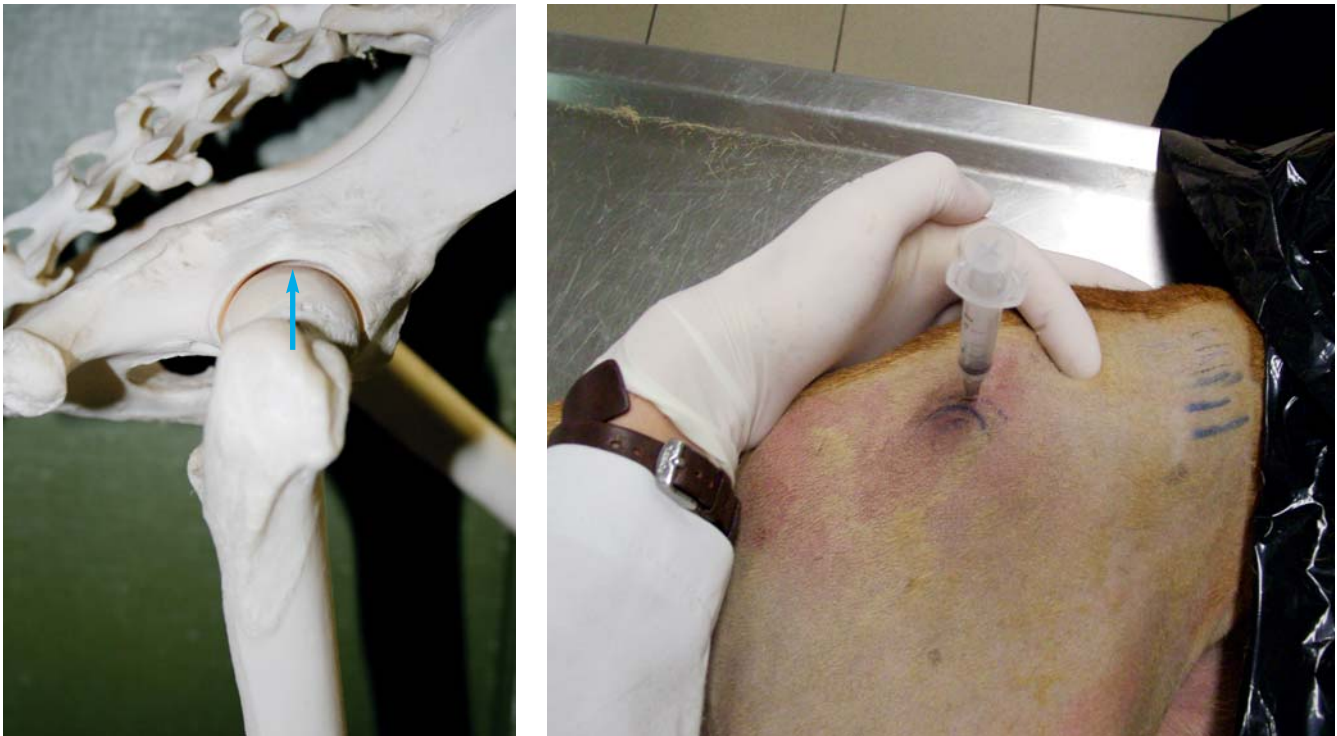

Figure 4. Bony specimen and cadaver specimen of the hip joint. The dog is placed in lateral recumbency with the hind limb parallel to the table surface and in neutral position. The needle is inserted closely dorsal to the greater trochanter and perpendicular to the long axis of the limb.

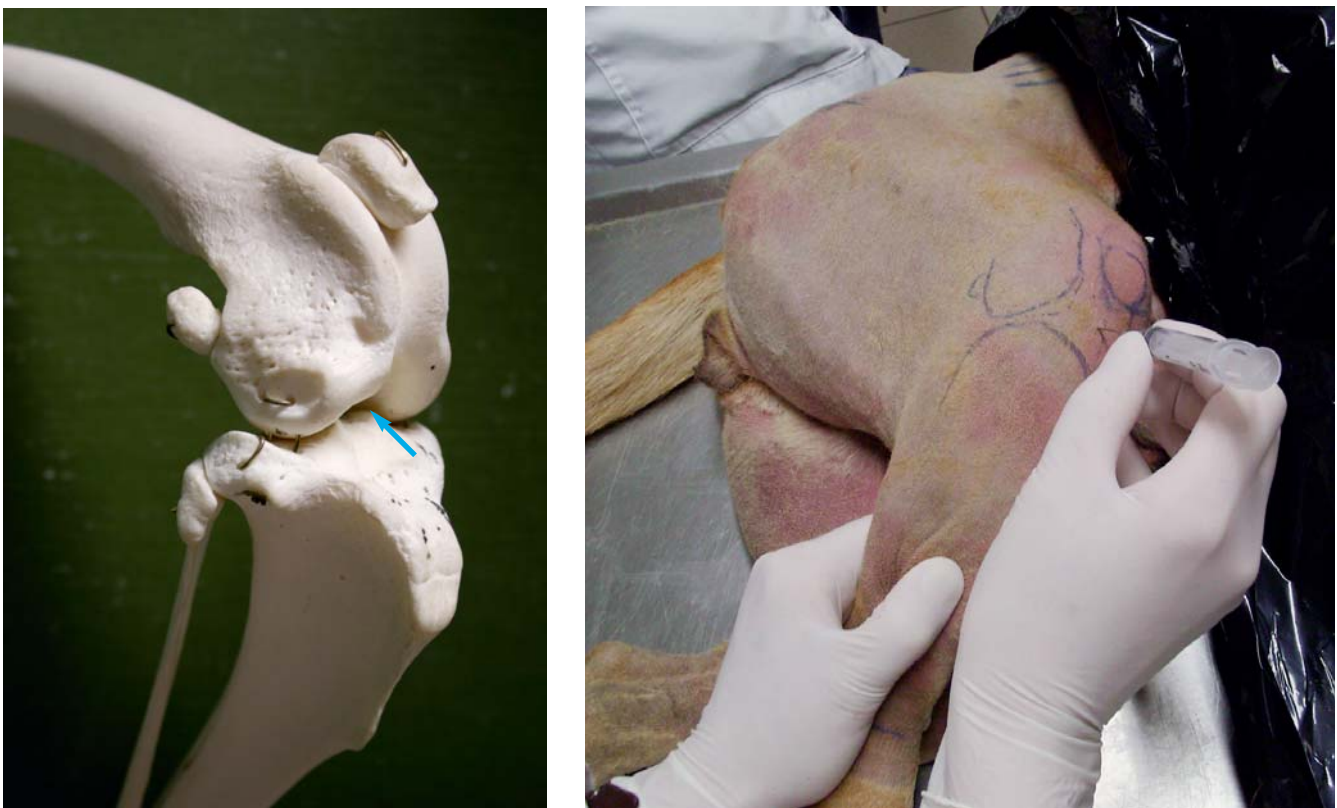

Figure 5. Bony specimen and cadaver specimen of the stifle joint. The dog is placed in lateral recumbency with the stifle flexed to 90°. The joint can be punctured laterally or medially to the straight patellar ligament. The needle is directed towards the centre of the intercondylar joint space and parallel to the tibial plateau at an angle of 45° to the skin, midway between the patella and the tibial tuberosity.

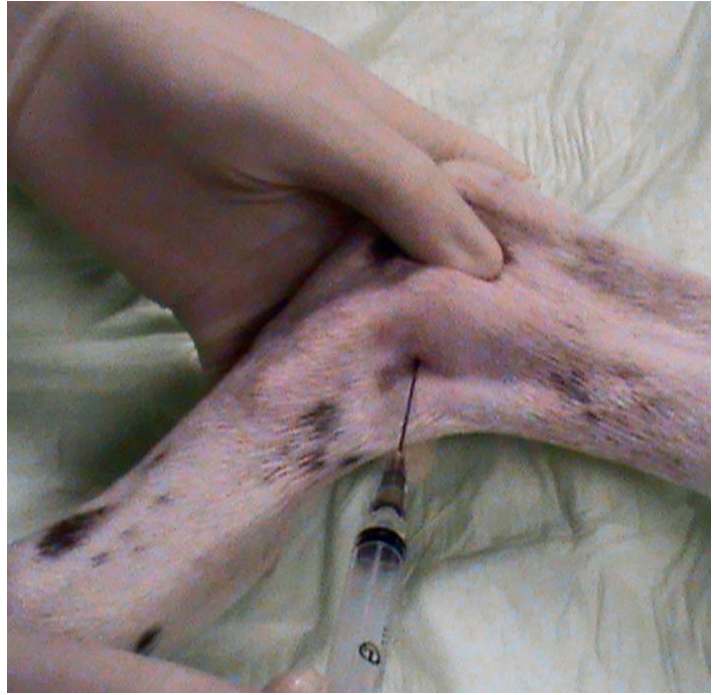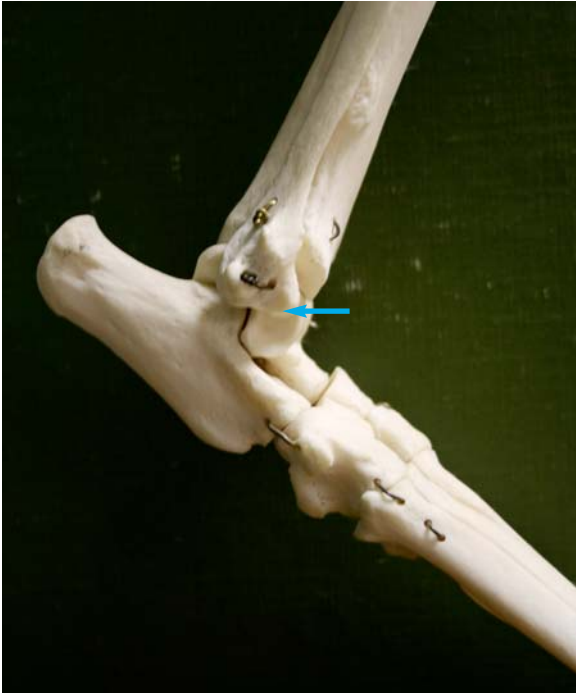


Figure 6. Bony specimen and cadaver specimen of the hock joint. The dog is positioned in lateral recumbency, with the affected limb uppermost. The joint can be punctured dorsolaterally, i.e. cranial to the ridges of the trochlea and distal to the tibia. Alternatively, the joint can be punctured plantarolaterally, between the distal part of the tibia and the calcaneus. In mildly distended cases, the joint fluid should be pushed towards the puncture side.

RESULTS

A total of 190 client-owned dogs were included in this study. In 161 dogs, front limb lameness and in 29 dogs, hind limb lameness was observed.

Sedation with acepromazine and methadone was sufficient to allow IA anesthesia in the different joints. However, some of the dogs needed to be restrained on the table by two or three assistants. A small percentage of the dogs demonstrated pain when the needle penetrated the skin or when intra-articular pressure increased during the injection of mepivacaine. On the other hand, sedation with medetomidine allowed painless injection and the dogs were held by only one person for safety and positioning, while another person was performing the injection.

A temporarily amelioration of lameness (minimal two grades on a scale of 0 to 10) after intra-articular injection was noted in 166 dogs (87% positive effect), which confirmed that the suspected joint was the localization of the problem. In 24 dogs (13%), the intra-articular anesthesia did not improve the lameness. Further diagnostic work-up using scintigraphy, CT or MRI demonstrated pathology in the injected joint of 18 dogs. Those cases were called false negative. In six dogs, the cause of lameness was not situated in the injected joint. In those cases, the result of the intra-articular anesthesia was true negative. The sensitivity and specificity of the effect of intra-articular anesthesia were 90% and 100% respectively. The 95% confidence interval ranged from 0.85 to 0.95. The number of joints (positive, negative or false negative), the ef-

fect of the intra-articular anesthesia and the final diagnosis are listed in Table 1.

DISCUSSION

This study was conducted to evaluate the possibilities and limitations of diagnostic intra-articular anesthesia in dogs as an alternative to scintigraphy for the localization of lameness. In man, intra-articular anesthesia is used to specify the localization of a problem within a certain painful region (Mitchell et al., 1995). In horses, it is applied in a systematic way, starting distally and moving proximally until the test is positive (Verschooten, 1985; Stashak, 2002). In the present study, the most suspected joint was punctured first, based on the history, clinical and radiographic findings and the authors' clinical experience. A systematic approach as used in the horse is not applicable in the dog: dogs need to be sedated to allow an intra-articular injection. They need to be retained on a table, and the injection of the small canine joints is not always easy. Compared to the horse, there is a lesser need for intra-articular anesthesia of the toe and carpal joints, because in the dog, these joints are easy to examine clinically and radiographically, and the frequency of the problem leading to lameness is rather low.

Some dogs may tolerate an intra-articular injection without sedation, but the risk of a pain or defense reaction and subsequent iatrogenic damage during the procedure is increased. Therefore, sedation was used in all of the dogs of the present study. In a previous study, two sedation protocols (acepromazine and methadone

Table 1. The results of 190 joints injected by means of intra-articular anesthesia.

Joint	Total joints	Positive	False negative	Negative	Diagnosis
Elbow	131	110	15	6	All
	111	97	14		MCD
	2	2	0		MCD + OCD
	1	1	0		OCD
	1	1	0		Loose anconeal process
	5	4	1		Flexor tendon enthesopathy
	1	1	0		Incomplete ossification of the humeral condyle
	4	4	0		Infection
	6	0	0	6	*(see below)
Shoulder	30	28	2	0	All
	18	18	0		OCD
	9	8	1		Partial rupture biceps tendon
	9	8	1		Calcified body
	1	1	0		Infection
Tarsus	2	2	0	0	All
	1	1	0		OCD
	1	1	0		Old fracture calcaneus
Stifle	23	22	1	0	All
	2	2	0		OCD
	8	7	1		Partial rupture cranial cruciate ligament
	6	6	0		Meniscal injury
	2	2	0		Patellar luxation
	1	1	0		Tendinosis patellar ligament
	4	4	0		Infection
Hip	4	4	0	0	All
	4	4	0		Hip dysplasia

*panosteitis (2), paralysis of the radial nerve (1), tumor of the scapula (1), OCD of the shoulder (1), fractured sesamoid bone (1)

or medetomidine) were examined for use prior to intra-articular anesthesia in the dog (Van Vynckt et al., 2011). No important changes in lameness due to sedation and no major differences between the two proposed sedation protocols were observed. This was also experienced in the present study.

The approach of the joints and puncture sites described in this study aims to minimize iatrogenic cartilage lesions and morbidity by avoiding neurovascular bundles, tendons and ligaments. Careful handling of the needle is required to avoid iatrogenic damage and pain reactions of the sedated dog, in particular in the acepromazine protocol. Puncturing the small canine joints is often difficult. The joint space of the shoulder and the hip is difficult to localize, because of the large muscular layer. The carpal and tarsal joints are superficial and lightly palpable, but they are small. The elbow and stifle joints are quite easy to puncture, but synovial fluid cannot always be aspirated. One of the prerequisites for a valuable test is the correct intra-articular position and subsequent injection. Therefore, intra-articular anesthesia should be considered an advanced technique, and the clinician needs to be experienced in puncturing joints. Lack of experience

could be considered as a limitation of the technique, despite its simplicity and direct result.

Another limitation of the present study was the use of a visual scoring method for the evaluation of lameness instead of an objective method of measurement, more specifically, a force plate or pressure plate (Oostlerlinck et al., 2011; Quinn et al., 2007). However, the use of a force plate is very time consuming (Voss et al., 2007), and hence not easily applicable when a large group of patients needs to be examined during the daily clinical activities. In our study, inter- and intra-observer variations were avoided by using several experienced observers, judging the animal during direct inspection and afterwards, on randomized video sequences. Furthermore, the applied 11-point NRS system allowed the detection of more subtle lameness changes than a typical 4- or 5-point scale (Arkell et al., 2006). Moreover, the videotapes used in the different studies allowed the visualization of subtle changes in lameness by repeating the different sequences of the same dog.

The high sensitivity and specificity of intra-articular anesthesia suggest that this technique is a very reliable method to detect the source of lameness in a dog.

It confirmed the suspected joint as the localization of the problem in 166 of the 190 cases (87%). In 3.2 %, the method tested negative, meaning that the problem was not located within the injected joint. In 9.5 %, the test was falsely negative, meaning that the problem was located within the injected joint but the lameness was not significantly decreased. This is one of the major limitations of the technique. Therefore, negative results should always be interpreted with care, and other diagnostic techniques should be used for further work-up.

In this study of 190 joints, the intra-articular anesthesia of 131 elbows and 30 shoulders was described. The distribution of the joint disorders in this series of patients reflects the more challenging orthopedic cases as has been described in the literature (Cook and Cook, 2009). Especially front limb lameness in dogs often leads to a clinical dilemma in terms of definitive localization and determination of the cause. More specifically, the most common sources of lameness proven to be difficult to localize and definitively diagnose, involve the elbow and/or shoulder joints (Cook and Cook, 2009).

Front limb lameness associated with elbow pain is common in large breed dogs, and medial coronoid disease (MCD) is the most frequent cause (Meyer-Lindenberg et al., 2002). Radiography has been used as a surveying tool for the assessment of elbow dysplasia for many years, although the elbow pathology is not always clear on plain radiographs (Punke et al., 2009). In cases in which the orthopedic examination and/or conventional radiography do not enable the clinician to localize the painful joint, intra-articular anesthesia could be very useful. In the present study, 14 dogs with MCD showed a false negative effect of the intra-articular anesthesia. The influence of the technique on different forms of medial coronoid disease has been evaluated in another clinical study (Van Vynckt et al., 2012). It was concluded that lameness caused by all types of MCD could significantly be decreased with intra-articular anesthesia, even in case of minimal lesions. However, in 9.5%, the intra-articular anesthesia was false negative, suggesting that a negative test does not exclude the presence of a coronoid problem.

In contrast to more distally located joints, the shoulder is more challenging for the evaluation of joint effusion and pain, because of the large muscular layer. However, intra-articular anesthesia is less often needed for shoulder problems because of the clear clinical and radiographic lesions of the most common shoulder problem, osteochondrosis dissecans (OCD). Other shoulder disorders, such as biceps problems and calcifications at the caudal rim of the glenoid cavity, may be more challenging and intra-articular anesthesia may contribute to the further examination by confirming the shoulder as the problem site. Full assessment of the shoulder joint may require other diagnostic tests and more advanced imaging methods, such as ultrasound, contrast arthrography, CT, magnetic resonance imaging and arthroscopy (Long and Nyland, 1999; Murphy et al., 2008, van Bree et al., 1992). Anesthetic arthro-

graphy is a combination of intra-articular anesthesia and a contrast medium, and can be performed to ensure intra-articular injection and to combine diagnostic anesthesia with another diagnostic imaging technique. In the dog's shoulder, positive contrast arthrography enhances the visualization of important intra-articular structures, including the articular cartilage, the synovial membrane outline and the biceps tendon (van Bree, 1993; Allan, 2007). A recent study has demonstrated that the quality of the shoulder arthrograms stays unchanged and mixing contrast medium with a local anesthetic does not interfere with the effect on lameness (Van Vynckt et al., 2012).

The carpus consists of three levels of joints and surrounding joint capsule and ligaments. The most common conditions are fractures of the individual bones or trauma to the collateral ligaments, which can easily be diagnosed on palpation and radiography. Diagnosing the less common mild carpal disorders may be difficult, and in those cases, intra-articular anesthesia may be of help. In the present study, the necessity of the use of intra-articular anesthesia in the carpus was not encountered.

In the described series, intra-articular anesthesia for hind limb lameness was only performed in 29 of the 190 joints. In dogs with hind limb lameness, the hip and stifle joints are commonly both affected. Only four hip joints were injected with a local anesthetic. Hip problems are easily diagnosed based on the clinical and radiographic findings. Only in case of discrete pathology or when multifocal lesions are present, intra-articular anesthesia may be useful. The technique was more often performed in the stifle; in 23 of the 29 cases. Most stifle problems are caused by a ruptured cruciate ligament with or without a meniscal tear. This was also reflected in the present study. Cranial cruciate ligament ruptures are characterized by instability and clear radiographic changes. Diagnosis may be difficult when a partial cruciate ligament rupture is present without palpable instability and with minimal radiographic changes. The diagnosis of meniscal tears can equally be problematic because a typical click is often absent. Also when stifle lesions are found in addition to other joint problems such as hip dysplasia, intra-articular anesthesia can be useful.

In contrast to the horse, the canine tarsal joint rarely required intra-articular anesthesia. Not only is this joint less frequently affected with lameness problems, the localization of the tarsus is usually quite evident during clinical examination.

As general conclusion, we can state that intra-articular anesthesia is a feasible technique for the experienced practitioner and can be used in different joints in the dog. Although this clinical study allowed us to draw conclusions about the possibilities and limitations of intra-articular anesthesia in different joints, it did not focus on the severity and type of lesions. This seemed especially interesting in the elbow joint because of the different appearances of medial coronoid lesions. Another aspect, which required further investigation, was

the combination of intra-articular anesthesia and arthrography of the shoulder. Both themes have been further elaborated in a detailed study (Van Vynckt et al., 2012).

REFERENCES

- Allan G.S. (2007). Radiographic signs of joint disease in dogs and cats. In: Thrall D.E. (editor). *Textbook of Veterinary Diagnostic Radiology*, 5th ed, Saunders Elsevier, p. 317-359.
- Arkel M., Archer R. M., Guitian F. J., May S. A. (2006). Evidence of bias affecting the interpretation of the results of local anaesthetic nerve blocks when assessing lameness in horses. *The Veterinary Record* 159, 346-349.
- Borer K. (2006). Local analgesic techniques in small animals. *In Practice* 28, 200-207
- Cook J. L., Cook C. R. (2009). Bilateral shoulder and elbow arthroscopy in dogs with forelimb lameness: diagnostic findings and treatment outcomes. *Veterinary Surgery* 38, 224-232.
- Crawford R.W., Gie G.A., Ling R.S., Murray D.W. (1998). Diagnostic value of intra-articular anaesthetic in primary osteoarthritis of the hip. *Journal of Bone & Joint Surgery British* 80(2), 279-281.
- Houlton J. (1994). Ancillary aids to the diagnosis of joint disease. In: Houlton J., Collinson R. (editors). *Manual of Small Animal Arthrology*. Iowa, USA, Iowa State University Press, 37.
- Long C.D., Nyland T.G. (1999). Ultrasonographic evaluation of the canine shoulder. *Veterinary Radiology & Ultrasound* 40(4), 372-379.
- Meyer-Lindenberg A., Langhann A., Fehr M., Nolte I. (2002). Prevalence of fragmented medial coronoid process of the ulna in lame adult dogs. *The Veterinary Record* 151, 230-234.
- Mitchell M. J., Bielecki D., Bergman A. G., Kursunoglu-Brahme S., Sartoris D. J., Resnick D. (1995). Localization of specific joint causing hindfoot pain: value of injecting local anesthetics into individual joints during arthrography. *American Journal of Roentgenology* 164, 1473-1476.
- Murphy S.E., Ballegeer E.A., Forrest L.J., Schaefer S.L. (2008). Magnetic resonance imaging findings in dogs with confirmed shoulder pathology. *Veterinary Surgery* 37(7), 631-638.
- Oosterlinck M., Bosmans T., Gasthuys F., Polis I., Van Ryssen B., Dewulf J., Pille F. (2011). Accuracy of pressure plate kinetic asymmetry indices and their correlation with visual gait assessment scores in lame and nonlame dogs. *American Journal of Veterinary Research* 72, 820-825.
- Punke J. P., Hulse D. A., Kerwin S. C., Peycke L. E. and Budsberg S. C. (2009). Arthroscopic documentation of elbow cartilage pathology in dogs with clinical lameness without changes on standard radiographic projections. *Veterinary Surgery* 38, 209-212.
- Quinn M. M., Keuler N. S., Lu Y., Faria M. L., Muir P., Markel M. D. (2007). Evaluation of agreement between numerical rating scales, visual analogue scoring scales, and force plate gait analysis in dogs. *Veterinary Surgery* 36, 360-367.
- Stashak T.S. (2002). Examination in lameness. In: Stashak T.S., Adams O.R. (editors). *Adam's Lameness in Horses*. Baltimore, Lippincott Williams & Wilkins, p. 168-180.
- Vanbree H., Vanryssen B., Desmidt M. (1992). Osteochondrosis lesions of the canine shoulder - Correlation of positive contrast arthrography and arthroscopy. *Veterinary Radiology & Ultrasound* 33(6),342-347.
- van Bree H. (1993). Comparison of the diagnostic accuracy of positive-contrast arthrography and arthrotomy in evaluation of osteochondrosis lesions in the scapulohumeral joint in dogs. *Journal of the American Veterinary Medical Association* 203, 84-88.
- Van Vynckt D., Polis I., Verschooten F., Van Ryssen B. (2010). A review of the human and veterinary literature on local anaesthetics and their intra-articular use. Relevant information for lameness diagnosis in the dog. *Veterinary and Comparative Orthopaedics and Traumatology* 23, 225-230.
- Van Vynckt D., Samoy Y., Polis I., Bosmans T., Verschooten F. and Van Ryssen B. (2011). Evaluation of two sedation protocols for use before diagnostic intra-articular anaesthesia in lame dogs. *Journal of Small Animal Practice* 52, 638-644.
- Van Vynckt D., Verhoeven G., Saunders J., Polis I., Samoy Y., Verschooten F., Van Ryssen B. (2012). Diagnostic intra-articular anaesthesia of the elbow in dogs with medial coronoid disease. *Veterinary and Comparative Orthopaedics and Traumatology* 25, 307-313.
- Van Vynckt D., Verhoeven G., Van Bree H., Polis I., Samoy Y., Verschooten F., Van Ryssen B. (2012). Anaesthetic arthrography of the shoulder joint in dogs. *Veterinary and Comparative Orthopaedics and Traumatology*. Submitted.
- Vasseur P., Slatter D. (1993). Gait analysis and orthopaedic examination. In: Slatter D. (editor). *Textbook of Small Animal Surgery*. Philadelphia, Saunders, p. 1577-1586.
- Verschooten F. (1985). Examination of lameness in horses - Some important accents 1. *Vlaams Diergeneeskundig Tijdschrift* 54, 359-381.
- Voss K., Imhof J., Kaestner S., Montavon P. M. (2007). Force plate gait analysis at the walk and trot in dogs with low-grade hindlimb lameness. *Veterinary and Comparative Orthopaedics and Traumatology* 20, 299-304.