

The use of vacuum-assisted wound closure to enhance skin graft acceptance in a horse

Het gebruik van vacuümgeassisteerde wondbehandeling bij het paard om het aanslaan van huidgreffen te bevorderen

M. Jordana, E. Pint, A. Martens

Department of Surgery and Anesthesiology of Domestic Animals, Faculty of Veterinary Medicine, Ghent University, Salisburylaan 133, 9820 Merelbeke, Belgium

mireia.jordanagarcia@ugent.be

ABSTRACT

A 16-year-old horse was admitted to the clinic of the Department of Surgery and Anesthesiology of Domestic Animals of the Faculty of Veterinary Medicine (Ghent University) for the treatment of a very large, non-healing wound extending over the dorsomedial and dorsolateral aspects of the left metatarsus. Surgical debridement of exuberant granulation tissue and new bone was performed under general anesthesia, followed by standard wound care under a bandage. Once a new bed of healthy granulation had formed, skin grafting was performed using the punch graft method. Due to the presence of a significant amount of wound exudate, cast immobilization was considered to be contraindicated. Instead, vacuum-assisted closure (VAC) therapy was used as a method of securing the skin grafts to the wound bed during the first days post-operatively. After five days of VAC therapy, the wound dressing was removed and an acceptance of nearly 100% of the punch grafts was observed. Complete epithelialization of the wound was evident 42 days after skin grafting. As far as the authors know, this is the first report describing the use of VAC therapy as a method of wound management in combination with punch grafting on the distal limb of a horse.

SAMENVATTING

Een 16-jarig paard werd opgenomen in de kliniek van de Vakgroep Heelkunde en Anesthesie van de Huisdieren van de Faculteit Diergeneeskunde (UGent) voor de behandeling van een zeer grote, niet-helende wonde ter hoogte van het dorsomediaal en dorsolateraal aspect van de linkermetatarsus. Aanvankelijk werden het overtollige granulatieweefsel en de nieuwbeenvorming chirurgisch verwijderd onder algemene anesthesie, gevolgd door standaardwondzorg onder verband. Van zodra een nieuw en gezond granulatieweefselbed gevormd was, werd een huidtransplantatie met huidgreffen uitgevoerd. Immobilisatie door middel van een gipsverband was niet aangewezen omdat de wonde sterk exsudatief was. In plaats daarvan werd een nieuwe methode, de vacuümgeassisteerde wondbehandeling (VAC), toegepast om het aanslaan van de greffen te bevorderen. Na vijf dagen VAC-therapie werd de wondbedekking verwijderd en werd vastgesteld dat nagenoeg 100% van de huidgreffen aangeslagen was. Tweeënveertig dagen na de huidtransplantatie was de wonde volledig geëpitheliseerd.

Voor zover de auteurs hebben kunnen nagaan, is dit de eerste beschrijving van het gebruik van de VAC-therapie bij de behandeling van een wonde in combinatie met een transplantatie van huidgreffen ter hoogte van het distale lidmaat bij een paard.

INTRODUCTION

Traumatic wounds occur frequently in horses and a significant number of them need to heal by second intention due to massive tissue loss, significant contamination, continuous movement, skin tension and/or the passage of a long interval of time between injury and treatment (Theoret, 2006). Wounds of the distal extremities in horses heal less rapidly than those of the trunk because of comparatively slower rates of contraction and epithelialization (Hanson, 2008). Unsatisfactory healing with the formation of exuberant granulation tissue or dense fibrogranuloma is therefore frequently observed (Schumacher, 2008). Second intention wound healing can be improved with the use of

the appropriate primary wound dressings, depending on the stage of wound healing (Theoret, 2006). Skin grafting also provides an efficient and cost-effective means of wound management and can be performed on fresh wounds (created either surgically or traumatically) or on granulating wounds (Schumacher, 2008).

Vacuum-assisted closure (VAC) is a method of wound management that has been used in human surgery for several years. The technique applies subatmospheric pressure to the wound, which – in combination with an open cell foam and adherent occlusive dressing – creates a controlled closed wound environment (Wilson, 2008). The benefits of VAC therapy have been demonstrated in several animal and human studies. This type of wound management enhances

wound healing because it allows adequate drainage of the wound, it accelerates granulation tissue formation, it increases local tissue blood flow and it decreases the total bacterial number in the wound (Morykwas *et al.*, 1997). There are only a few studies reporting the use of VAC therapy in horses. This type of wound management has been used alone to accelerate second-intention wound healing in a large traumatic lesion (Gemeinhardt and Molnar, 2005) and in cases of non-healing wounds (Perrin and Gehin, 2011). Other authors have reported the use of VAC therapy combined with free skin grafting when using the MEEK technique (Rijkenhuizen *et al.*, 2005).

This case report is the first to describe the clinical use of VAC therapy as a method of wound management combined with punch skin grafting in a very large, chronic wound of the distal extremity of a horse.

CASE REPORT

Case history

A 16-year-old Warmblood gelding was referred to the Veterinary Hospital of Ghent University with a very large 3-month-old wound at the level of the metatarsus of the left hind limb (Figure 1). The injury had been sustained on fence wire and had been treated by the referring veterinary surgeon since the first day, but without success.

On admission, the animal was in relatively poor physical condition. A low grade lameness of the left hind limb was evident. The horse demonstrated the characteristic gait of an animal with severed extensor tendons. The wound on the dorsal aspect of the left metatarsus was large (approximately 20 cm diameter) and extended both medially and laterally. A significant amount of exuberant granulation tissue was present. This tissue was pale pink with an irregular surface and was malodorous. The affected limb also showed a significant degree of lymphangitis with cellulitis of the soft tissues from the pastern to the tarsus. Radiographic examination (lateromedial and dorsoplantar projections) showed extensive new bone formation on the dorsal, medial and lateral aspects of the metatarsus (Figure 2) and a large and irregular soft tissue swelling at this level.

Preparation of the wound bed

Surgical debridement of the wound was performed under general anesthesia, with the horse in dorsal recumbency and with a tourniquet applied proximal to the hock. All exuberant granulation tissue was excised, the wound edges were refreshed and the periosteal exostoses were removed under fluoroscopic guidance. By the end of the procedure, two areas of exposed bone on the dorsomedial and dorsolateral aspects of the third metatarsal bone were visible, separated by a band of

scar tissue that had replaced the lacerated extensor tendon (Figure 3). After thorough lavage, the wound was covered with an antiseptic dressing (Kerlix®) and a full limb Robert Jones bandage was applied. Recovery from general anesthesia was uneventful.

Post-operative radiographic examination revealed successful removal of the periosteal exostoses (Figure 4). Because of the degree of preoperative wound contamination, the exposure of bone and soft tissues and the results of bacteriological examination from a post-operative sample, the horse was treated with oral doxycycline for 40 days (Doxyral 50%®, 20 mg/kg bwt, twice a day). Non steroidal anti-inflammatory drugs were administered for five days (Finadyne® paste, flunixin meglumine, 1.1 mg/kg bwt, once a day, orally). The wound was kept covered with a bandage and treated with different primary wound dressings according to the stage of wound healing. The bandages were changed every one to two days during the granulation period, before skin grafting. During the first ten days after surgery, an alginate dressing (Curasorb®) covered with an antiseptic gauze bandage (Kerlix®) was used for its absorbing properties and to stimulate granulation tissue formation, especially over the areas of exposed bone. By the seventh day after surgery, the dorsomedial aspect of the metatarsus was covered with healthy granulation tissue and by the eleventh day the dorsolateral aspect was also covered. Seventeen days after surgery, the wound was completely covered with smooth, homogeneous granulation tissue. In view of the size and the location of the wound, it was decided to accelerate further healing with a skin graft. Over the next 11 days, the wound was prepared for grafting according to the recommendations of Wilmink *et al.* (2006). This consisted of daily bandage changes with the alternating topical application of two different antibiotic ointments: silver sulfadiazine (Flammazine®) and fucidinic acid (Fucidin® 2%). Whenever it was indicated, the granulation tissue was cut back to the level of the skin. Twenty-eight days after the initial surgery, the wound was considered ready for skin grafting, even though it remained very exudative (Figure 5).

Skin grafting procedure

The skin grafting procedure was performed under standing sedation, using the constant rate infusion of a 0.5 mg/ml detomidine 1% (Domosedan®) solution at 6 µg/kg/hr. The skin around the wound edges was shaved and aseptically prepared. The granulation tissue was rinsed with sterile physiologic isotonic solution. A full-thickness punch grafting technique was performed. Grafts were taken from beneath the mane on the left side of the neck. Eighty punch grafts of 8 mm diameter were harvested and were positioned into 6 mm punch gaps created in the granulation tissue of the wound (Figure 6a).

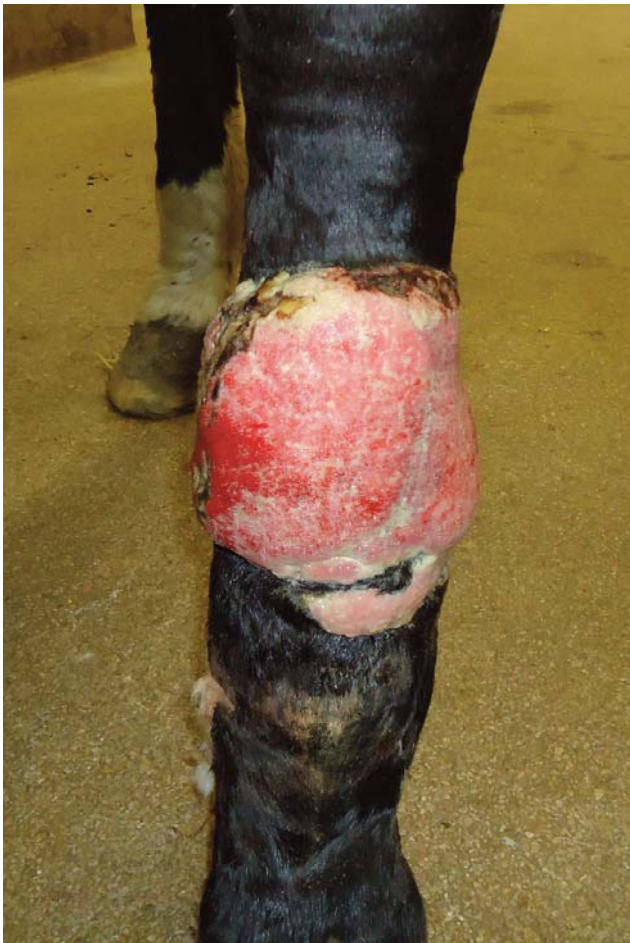

Figure 1. Appearance of the wound on the dorsomedial and dorsolateral aspects of the left metatarsus at the time of admission. Note the pale and irregular appearance of the exuberant granulation tissue.

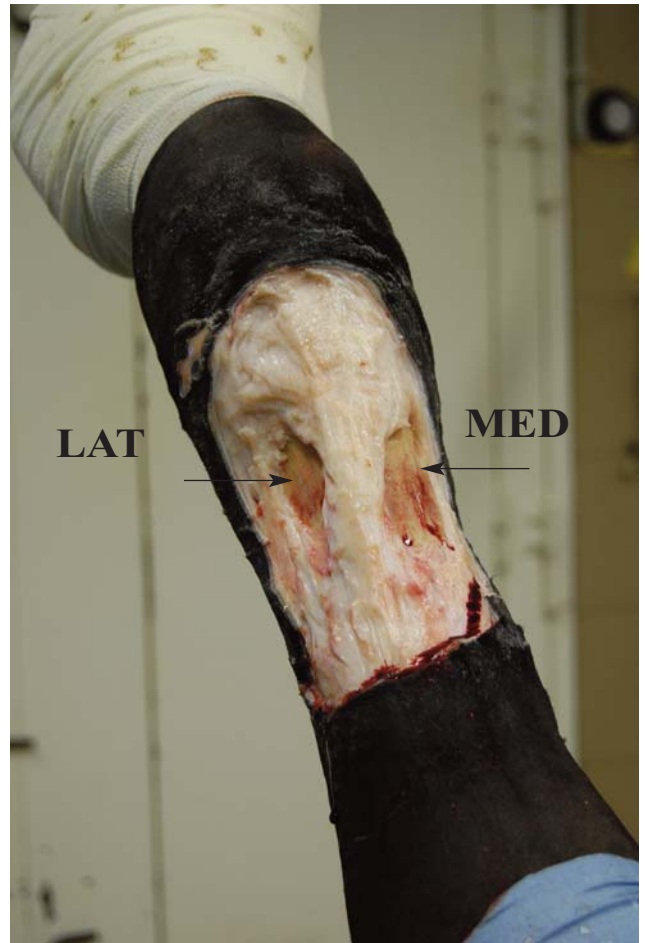

Figure 3. Intraoperative picture after all of the exuberant granulation tissue has been excised, the wound edges have been refreshed and the periosteal exostoses have been removed. There are two areas of exposed bone (arrows) – at the dorsolateral and the dorsomedial aspects of the wound.

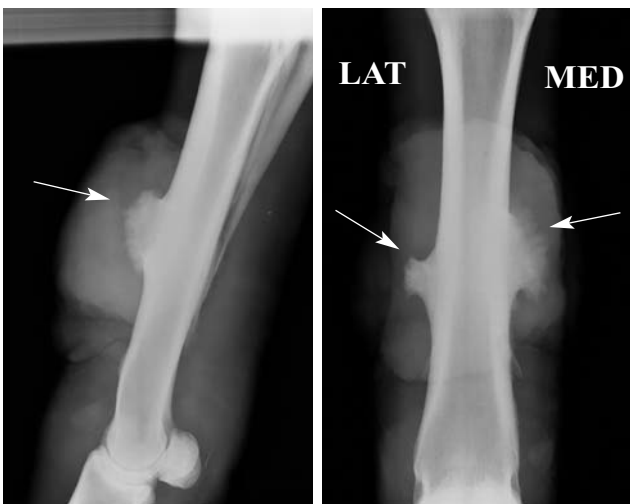


Figure 2. Lateromedial (left) and dorsoplantar (right) radiographic views of the left metatarsus prior to surgery. There is an extensive amount of soft tissue swelling at the dorsal, medial and lateral aspects of the left mid-metatarsus. At this level, the bone cortex shows a substantial amount of new bone formation (arrows).

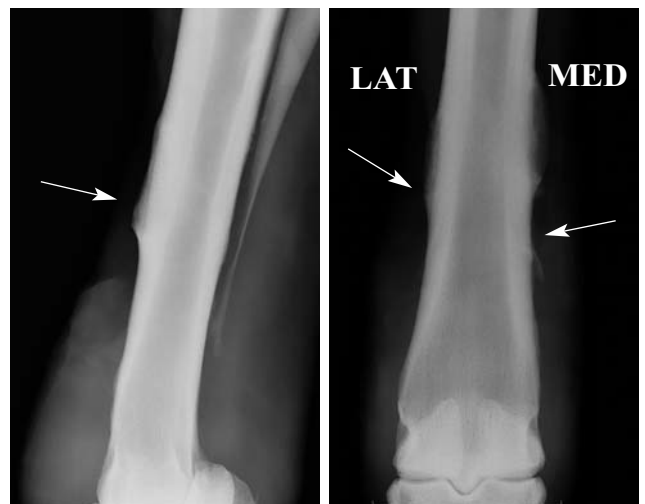

Figure 4. Postoperative lateromedial (left) and dorsoplantar (right) radiographs of the left metatarsus show that periosteal exostoses have been removed (arrows).

Application of the VAC® therapy system (KCI, Kinetic Concepts Inc., USA)

As the wound was still exudative at the time of skin grafting, the use of a cast to protect the wound and decrease movement at the level of the grafts was considered inappropriate. VAC therapy was chosen instead. The skin around the wound edges was meticulously degreased with ether (Figure 6a). The granulation bed, including the 80 punch grafts, was covered with white polyvinyl alcohol foam (VAC® White Foam Dressing) trimmed to the shape of the wound. This foam was fixed to the skin with adhesive drape (VAC® Drape) after the application of adhesive spray (Adhaesiv-Spray Hautkleber®) to the skin. A hole approximately 2 cm in diameter was created in the middle of the adhesive drape over the foam, and the SensaTRAC® Pad was applied over it to connect the foam to the VAC system (Figure 6b). The tubing was secured at the level of the tibia (Figure 6c) and a full limb Robert Jones bandage was applied over the VAC adhesive drape. Given the short length of the tubing and the wound location (hind limb), it was decided to cross-tie the horse in a narrow stable to restrict its movement. The VAC suction system (VAC ATS® Therapy Unit) was hung on the wall and was set at 125 mmHg of continuous negative pressure. This VAC unit contained a 500 ml VAC® Canister for collection of the aspirated exudate from the wound.

VAC therapy was continued for five days without bandage change during that period. Five days after the

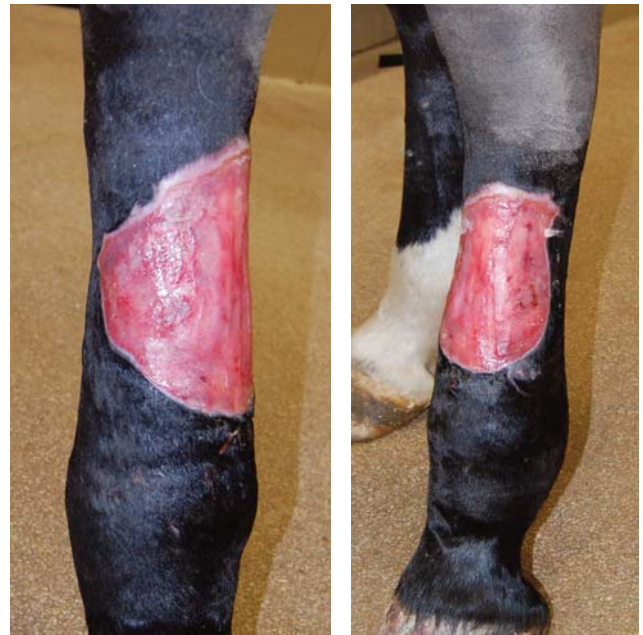

Figure 5. After 28 days (including an 11-day preparation period (with daily bandage changes with local application of fucidinic acid and silver sulfadiazine on alternating days), the granulation bed is now ready for skin transplantation.

skin grafting, 450 ml of hemorrhagic wound exudate had been collected and the VAC therapy was discontinued. Approximately 150 ml of wound exudate was collected during the first 24 hours. The following days, the amount of fluid aspirated in the canister progres-

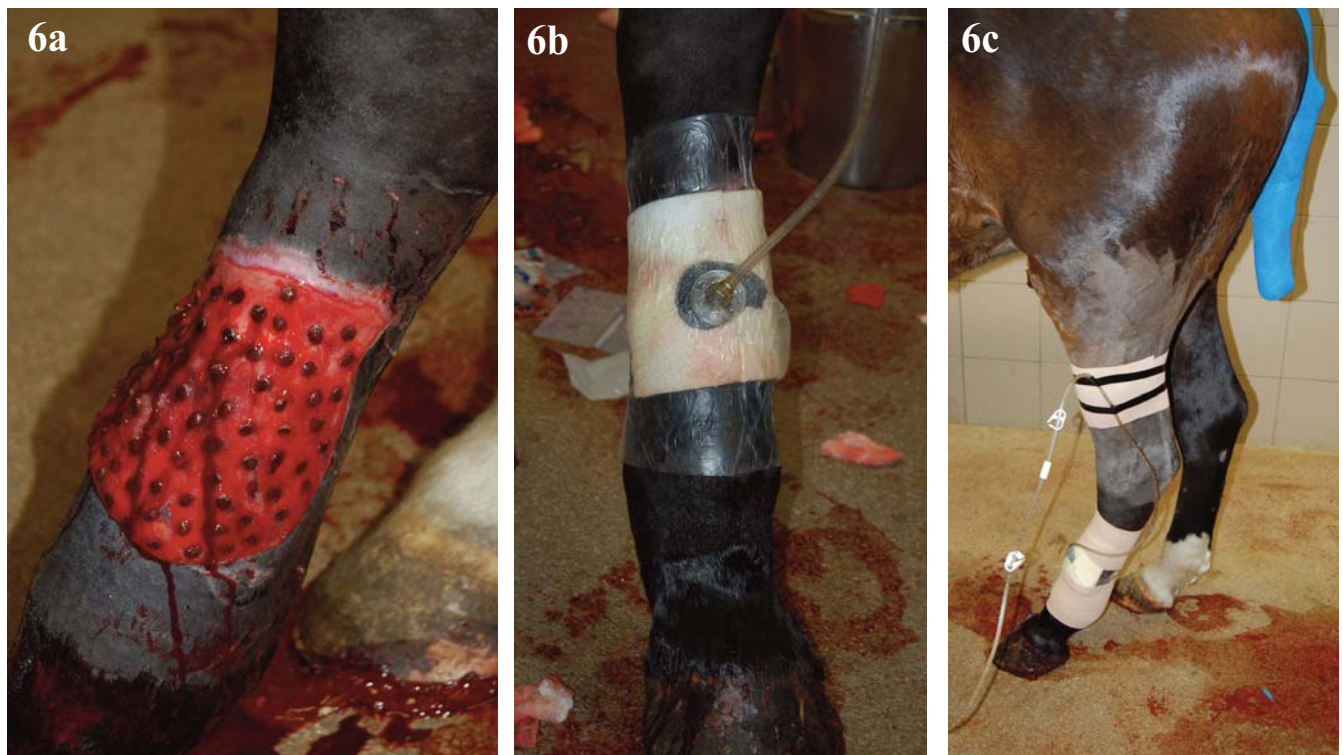


Figure 6. Application of the VAC system (day 0). 6a. Eighty punch grafts were placed. 6b. A polyvinyl alcohol foam (VAC® White Foam Dressing) was trimmed to the shape of the wound and fixed to the skin with an adhesive drape (VAC® Drape) and adhesive spray. A SensaTRAC® Pad connects the foam to the VAC system. 6c. The tubing is secured at the level of the tibia before application of a Robert Jones bandage.

sively decreased, with only 20 ml being collected by the fifth day.

At bandage removal, a graft acceptance of nearly 100% was observed, with granulation tissue of good quality. Hypergranulation did not occur, but the surface of the granulation tissue was irregular, most likely due to suction of the tissue onto the foam (Figure 7). The wound was no longer excessively exuding. A remarkable decrease in the limb edema was also observed. In order to achieve homogeneous granulation tissue, an ointment containing antibiotics and corticosteroids (Fucidin® hydrocortisone, 20 mg/g fucidinic acid and 10 mg/g hydrocortisone acetate) was applied topically and the bandage was replaced for two days. During the epithelialization phase, the limb was continuously kept under bandage with hydrophylic polyurethane foam (Kendall™) as the primary wound dressing. The bandages were changed every four to six days during this period. After the VAC therapy, the granulation tissue remained of good quality and the grafts gradually epithelialized to coalesce with each other and with the wound edges (Figure 8). Recurrent localized swelling of the granulation tissue between the grafts preventing epithelialization was observed at the distal and medial aspects of the limb and was treated

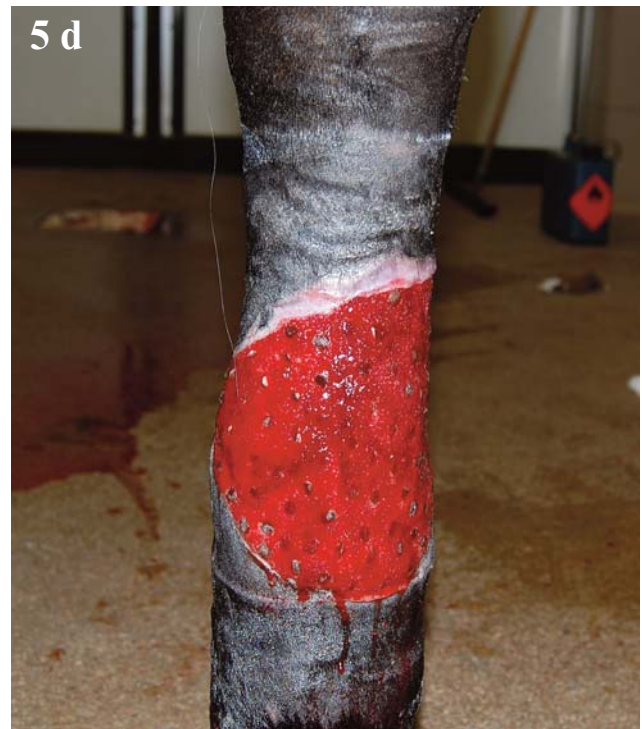

Figure 7. Appearance of the wound bed at the time VAC therapy was discontinued (d = days post skin grafting).

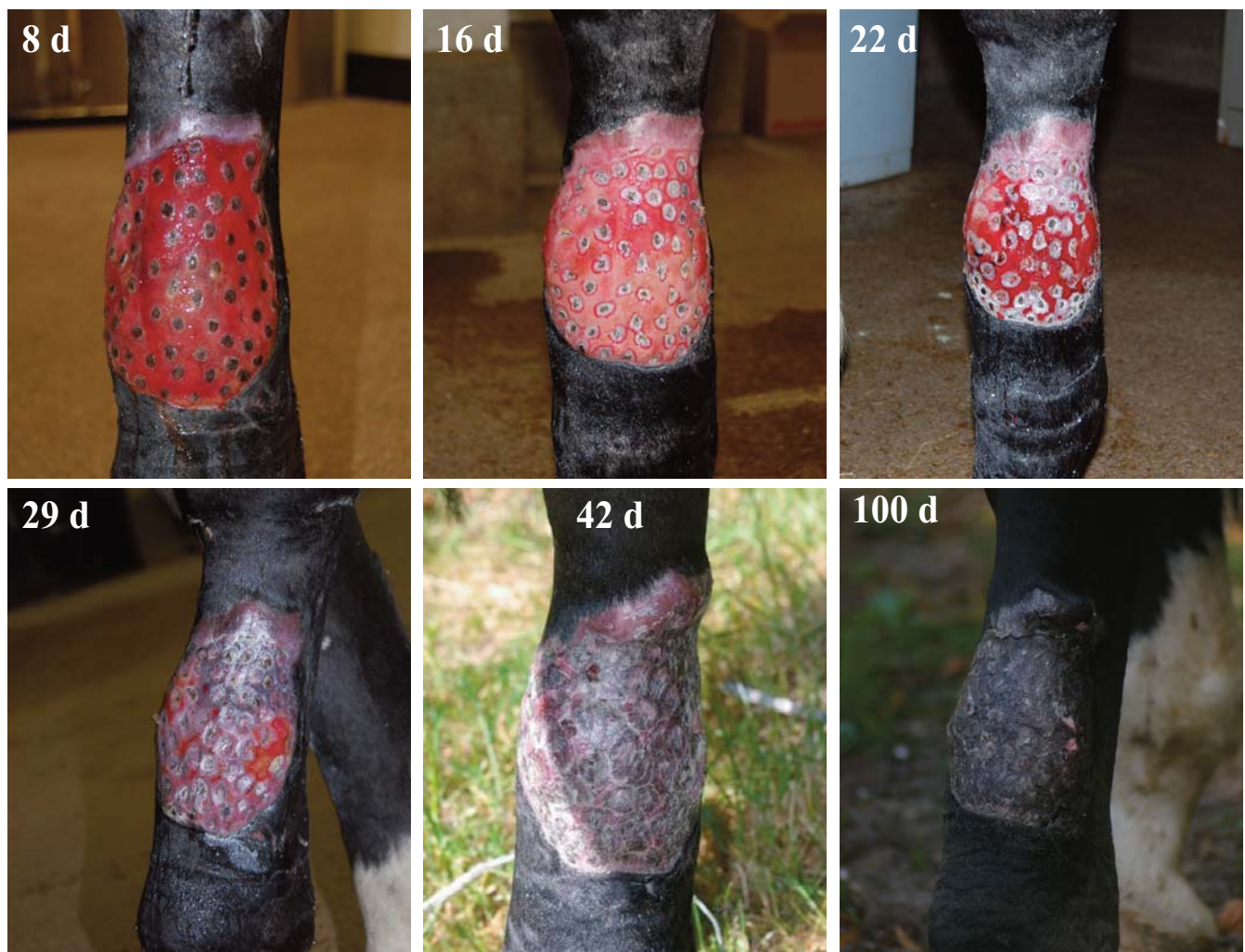

Figure 8. Progression of wound epithelialization after discontinuation of the vacuum therapy (d = days post skin grafting).

periodically with the Fucidin® hydrocortisone cream (never longer than two days). The horse was discharged from the clinic 37 days after the grafting procedure (66 days after initial surgery) and at this time he was walking comfortably, without limb swelling and with a wound that was almost completely epithelialized. Complete epithelialization was observed 42 days after skin grafting (Figure 8).

DISCUSSION

The present case shows how vacuum-assisted closure greatly enhances the acceptance of punch skin grafts in a large distal limb wound of a horse resulting in the survival of nearly 100% of the grafts. Previous studies report an acceptance rate of about 60% to 75% when this type of free skin grafts is used (Stashak, 1984). To optimize the acceptance of free grafts, the wound should be vascularized and free of infection and necrotic tissue (Schumacher 2008). The main reasons for graft failure are movement, infection, and fluid accumulation between the graft and the recipient bed (Schumacher, 2006). Fluid accumulation and movement result in loss of contact between the graft and the recipient bed, thus inhibiting fibrinous adhesion and revascularization. Infection of the granulation bed results in local inflammation with attendant exudation, which also separates the grafts from the recipient bed. Moreover, toxins and fibrinolytic substances are formed, which compromise the viability of the grafts and their adherence to the granulation tissue (Theoret, 2006).

Despite the thorough preparation of the granulation bed according to a strict protocol of daily application of a combination of broad spectrum antibiotic ointments, the wound in the horse in this report remained very exudative. Whether a (low-grade) infection was present was hard to determine. A wound is considered to be infected when more than 10^5 bacteria per gram of tissue are present, though quantitative bacteriology is not routinely performed (Schumacher, 2006). In the present case, the use of the VAC system was considered particularly advantageous in the exudative wound as the continuous application of a negative pressure resulted in permanent evacuation of the wound exudate, thus preventing graft loss. As has been shown in several studies, another advantage of the VAC therapy is the significant reduction in the number of bacteria in the wound, thus resolving a possible infection problem (Morykwas *et al.*, 1997; 2001; Wagner *et al.*, 2003; Moues *et al.*, 2004).

The standard protocol after punch grafting (according to the authors) is to apply a dressing and bandage over the grafted area, in combination with a cast when the wound is located at the level of the distal limb to decrease local movement (and thus failure of the grafts). The grafts are initially adhered to the recipient site by a fibrin matrix containing vessels and fibroblasts that bind to the collagen within the graft. Firm union of the grafts to the recipient bed occurs around the 10th day

(Tavis *et al.*, 1977; Schumacher, 2006). Therefore, it is not advisable to change the bandage for the first four to five days after grafting or for the first ten days if the limb has been casted. However, in the case of wound infection (for example with *Pseudomonas* or *Streptococci*), the bandage should be changed daily or even twice daily and an appropriate antimicrobial ointment should be applied to the grafted wound (Schumacher, 2006). In the present case, the bandage was not changed during the five days of VAC therapy, thereby allowing the formation of a constant wound environment and an appropriate union between graft and recipient bed. Another advantage of the use of the VAC system in comparison with the use of a distal limb cast is that possible complications related to casting in horses (such as pressure sores) are avoided (Levet *et al.*, 2009).

Edema or persistent swelling associated with wound inflammation is also one of the reasons for a lower rate of wound contraction and epithelialization because it increases the total circumference of the limb, thereby increasing the surface area of the wound (Hanson, 2008). In the present case, a significant decrease in limb edema was noted when the bandage was removed, a fact which was also considered to be a positive result of the VAC therapy.

The VAC system functioned properly and without complications during the five-day treatment period. However, other authors report difficulties in getting the system to function properly, despite the reports of good results with the use of VAC therapy in horses (Gemeinhardt and Molnar, 2005; Rijkenhuizen *et al.*, 2005; Perrin and Gehin, 2011). The most frequent problems are difficulties in maintaining an airtight seal over the wound and in keeping the VAC dressing in place due to the irregular geometry and motion at the distal limb of the horse. Intolerance to the VAC therapy due to sensitivity or pain caused by the negative pressure has also been reported in some patients. Excessive coiling and kinking of the evacuation or extension tubing may occur in horses that are allowed to move freely around the stable. Some authors have also reported problems positioning the vacuum pump to keep it out of the way yet readily accessible. In the present case, the VAC system was tolerated very well and the horse showed no signs of pain due to the negative pressure. A complete airtight seal was obtained by shaving the skin for 10 cm around the wound, degreasing it with ether, drying the skin carefully and applying adhesive spray under the adhesive drape. The application of a Robert Jones bandage over the VAC dressing provided additional support for maintaining the airtight seal. Cross-tying the horse in a special stable to restrict its movement allowed the vacuum pump to be hung up on the wall close to the hind limb. As a result, relatively short lengths of tubing could be used, thereby reducing the risk of coiling or kinking. Nowadays, portable battery-driven VAC systems are available (VAC Freedom™, KCI). These smaller, lighter units (1.45 kg versus 5.6 kg) may be fixed on the horse, thus allowing the patient to move

about freely in the stable. However, these new portable systems may be more inconvenient as they have smaller canisters (300 ml instead of 500 ml) and the batteries need recharging frequently.

Some authors have recommended bandage changes every two to three days when using VAC therapy, in order to prevent the granulation tissue from growing into the foam (Rijkenhuizen *et al.*, 2005). Different types of foams are available as primary dressings that can be applied over the wound when using VAC therapy. Polyurethane foams (V.A.C. GranuFoam®) are intended to stimulate granulation tissue formation while aiding wound contraction. Polyvinyl alcohol foams (V.A.C.® WhiteFoam Dressing), on the other hand, are hydrophilic dressings that control the growth of granulation tissue and prevent adherence of the foam to the wound (cf. the clinical guidelines provided by the VAC company KCI Medical Belgium bvba, Peer, Belgium). In the present case, polyvinyl alcohol foam was used, as there was no need for extra granulation tissue.

The VAC system can be used either with continuous or intermittent subatmospheric pressure. Experimental research in porcine models has shown that intermittent therapy (5 min on/ 2 min off) results in faster granulation tissue formation than continuous negative pressure alone (Morykwas *et al.*, 1997; 2001). On the other hand, the application of continuous negative pressure stimulates granulation tissue formation significantly faster than the application of simple, non-adherent dressings (Morykwas *et al.*, 1997; 2001). Continuous therapy is indicated during the first 48 hours of wound management but also in the following cases: 1) for patients that experience significant discomfort during intermittent therapy, 2) when difficulties occur while maintaining the airtight seal, 3) when there are high levels of drainage, 4) when skin flaps or grafts are treated to prevent shear or 5) when a splinting effect is required (cf. the clinical guidelines provided by the VAC company KCI Medical Belgium bvba, Peer, Belgium). In the present case, continuous negative pressure was used because of the presence of skin grafts and because there was no need to further stimulate the formation of granulation tissue.

The present case shows how the VAC system enhanced punch graft acceptance on the distal limb in a horse. The results are complementary to the previous reports of the use of VAC therapy in horses where this system was used to treat large traumatic and chronically infected wounds (Gemeinhardt and Molnar, 2005; Perrin and Gehin, 2011) or to enhance acceptance of MEEK micrografts (Rijkenhuizen *et al.*, 2005). All reports document the versatility of the VAC system for use in horses and the significant reduction in healing time that is obtained.

In summary, the present case demonstrates that vacuum-assisted wound closure therapy results in nearly perfect punch graft survival and significant enhancement of the healing of a large distal limb wound. This result, together with the results of previous re-

ports, is very encouraging and supports the use of VAC therapy in horses to treat large chronic or infected wounds and to enhance the acceptance of different types of skin grafting in different locations of the body. However, due to the design and characteristics of the procedure, careful patient selection is of paramount importance in the opinion of the authors. The ability to create and maintain a good vacuum over the surface of the wound determines the effectiveness of the system. Distal limb wounds may in this respect be good candidates for VAC therapy because a Robert Jones bandage can be applied over the VAC foam and bandage in order to prevent air leakage.

ACKNOWLEDGEMENTS

The authors would like to thank Jan and Els Bonaerens for all the help and technical support they provided during the period of VAC treatment. The authors would also like to thank the owners of this horse and all the colleagues and students from the veterinary hospital who helped with the intensive treatment of this horse.

REFERENCES

- Gemeinhardt K.D., Molnar J.A. (2005). Vacuum-assisted closure for management of a traumatic neck wound in a horse. *Equine Veterinary Education* 17, 27-33.
- Hanson R.R. (2008). Degloving injuries. In: T.S. Stashak and C.L. Theoret (editors). *Equine Wound Management*. 2nd Ed., Blackwell Publishing, Iowa, p. 427-443.
- Livet T., Martens A., Devisscher L., *et al.* (2009). Distal limb cast sores in horses: risk factors and early detection using thermography. *Equine Veterinary Journal* 41, 18-23.
- Morykwas M.J., Argenta L.C., Shelton-Brown E.I., McGuirt W. (1997). Vacuum-assisted closure: a new method for wound control and treatment: animal studies and basic foundation. *Annual of Plastic Surgery* 38, 553-562.
- Morykwas M.J., Faler B.J., Pearce D.J., Argenta L.C. (2001). Effects of varying levels of subatmospheric pressure on the rate of granulation tissue formation in experimental wounds in swine. *Annual of Plastic Surgery* 47, 547-551.
- Moues C.M., Vos M.C., Van Den Bemd G.C.M., *et al.* (2004). Bacterial load in relation to vacuum-assisted closure wound therapy: A prospective randomized trial. *Wound Repair and Regeneration* 12, 11-17.
- Perrin R., Gehin S. (2011). La gestion des plaies par la thérapie VAC® est-elle applicable chez le cheval? *Pratique Vétérinaire Equine* 43, 41-45.
- Rijkenhuizen A.B.M., Van den Boom R., Landman M., *et al.* (2005). Can Vacuum assisted wound management enhance graft acceptance? *Pferdeheilkunde* 21, 413-418.
- Schumacher J. (2006). Skin Grafting. In: J.A. Auer and J.A. Stick (editors). *Equine Surgery*. 3rd Ed., Elsevier, Missouri, p. 269-287.
- Schumacher J. (2008). Free skin grafting. In: T.S. Stashak and C.L. Theoret (editors). *Equine Wound Management*, 2nd ed., Blackwell Publishing, Iowa, p. 509-542.
- Stashak T.S. (1984). Skin grafting in horses. *Veterinary Clinics of North America Large Animal Practice* 6, 215.
- Tavis M.J., Thornton J.W., Harney J.H. *et al.* (1977). Mecha-



BREEDEX

BIJ ONS LEEFT DE PASSIE

VAN 7 TOT 9
DECEMBER 2011

IN BRUSSELS EXPO

VAKBEURS VOOR
DE PROFESSIONELE VEEHOUDERIJ

INFOS & TICKETING:
WWW.BREEDEX.BE

OPEN ALLE DAGEN
10u > 18u

- nism of skin graft adherence: collagen, elastin, and fibrin interactions. *Surgery Forum* 28, 522.
- Theoret C.L. (2006). Wound repair. In: J.A. Auer and J.A. Stick (editors). *Equine Surgery*. 3rd Ed., Elsevier, Missouri, p. 44-62.
- Wagner S., Coerper S., Fricke J., *et al.* (2003). Comparison of inflammatory and systemic sources of growth factors in acute and chronic human wounds. *Wound Repair and Regeneration* 11, 253-260.
- Wilmink J.M., Van den Boom R., Van Weeren P.R., Barneveld A. (2006). The modified Meek technique as a novel method for skin grafting in horses: evaluation of acceptance, wound contraction and closure in chronic wounds. *Equine Veterinary Journal* 38, 324-329.
- Wilson D.A. (2008). New and innovative approaches to wound closure. In: T.S. Stashak and C.L. Theoret (editors). *Equine Wound Management*. 2nd Ed., Blackwell Publishing, Iowa, p. 225-237.

