

First report of multinodular pulmonary fibrosis associated with equine herpesvirus 5 in Belgium

Eerste rapport van multinodulaire pulmonaire fibrose geassocieerd met equine herpesvirus 5 in België

¹K. Verryken, ²V. Saey, ²S. Maes, ⁴K. Borchers, ³G. Van De Walle, ²R. Ducatelle, ¹P. Deprez

¹ Department of Large Animal Internal Medicine

² Laboratory of Veterinary Pathology

³ Laboratory of Virology

Faculty of Veterinary Medicine, Ghent University,

Salisburylaan 133, B-9820 Merelbeke

⁴ Institute of Virology, Free University of Berlin

Phillipstrasse 13, Building Number 18, D-10115 Berlin

Kirsten.verryken@ugent.be

ABSTRACT

A 20-year-old horse was evaluated for symptoms of weight loss, anorexia, fever and lethargy. Clinical examination revealed tachypnea, poor body condition and increased breath sounds on auscultation. Ultrasound showed multiple consolidations on the lungs. Thoracic radiography revealed a severe nodular pattern. The horse was treated with antibiotics, corticoids and supportive medication. Since no improvement was observed, the horse was euthanized.

At necropsy, numerous coalescing fibrous nodules were present in the lungs. Histology revealed diffuse interstitial fibrosis and macrophages containing abundant eosinophilic cytoplasm and oval eosinophilic to amphophilic intranuclear inclusion bodies. Tissue samples tested positive for the presence of equine herpes virus 5 (EHV 5) on the basis of the polymerase chain reaction (PCR) test. A diagnosis of equine multinodular pulmonary fibrosis (EMPF) was made. This is the first report of EMPF in Belgium. EMPF can be suspected based on the ultrasonographic, radiographic and histological changes. EMPF is associated with EHV 5, but the etiological role of EHV 5 still remains to be proven.

SAMENVATTING

Een twintig jaar oude merrie werd aangeboden met anorexie, gewichtsverlies, koorts en sufheid. Tijdens het klinisch onderzoek werden een slechte lichaamsconditie, een verhoogde ademhalingsfrequentie en versterkte ademhalingsgeluiden aangetoond. Op het echografisch onderzoek waren meerdere verdichtingen in de long zichtbaar, hetgeen bevestigd werd door de radiografische bevindingen. Het paard werd behandeld met antibiotica en steroïden en kreeg een ondersteunende therapie, maar door het gebrek aan verbetering werd uiteindelijk beslist om het dier te euthanaseren. Op de lijkschouwing werden meerdere coalescerende nodulen in de longen aangetroffen. Histologie van de nodulen wees op een diffuse interstitiële fibrose met macrofagen die een sterk eosinofiel cytoplasma hadden, met de aanwezigheid van ovale eosinofiele tot amfofiële intranucleaire inclusies. Equine Herpesvirus (EHV) type 5 werd met PCR aangetoond in het weefsel van het paard. De diagnose van equine multinodulaire pulmonaire fibrose (EMPF) werd gesteld.

Dit is het eerste rapport van EMPF in België. EMPF kan gediagnosticeerd worden aan de hand van de echografische, radiografische en lijkschouwingsbevindingen. EHV5 lijkt gecorreleerd te zijn met EMPF, maar verder onderzoek is nodig.

INTRODUCTION

Chronic pulmonary disease in horses is mostly due to allergic bronchiolitis. In a minority of cases other types of underlying pathologies such as mycotic granulomas, lipid pneumonia, bacterial abscesses, silicate pneumoconiosis or neoplasia are found. In many cases, however, the etiology remains unknown (Buergelt *et al.*, 1986). Recently in the US, equine multinodular pul-

monary fibrosis (EMPF) has been reported as a new form of chronic pulmonary disease (Williams *et al.*, 2007).

EMPF is a fibrotic lung disease suspected to be associated with EHV 5 infection. The clinical signs include weight loss, anorexia, fever, lethargy and respiratory problems. Diagnosis is made post-mortem by necropsy and histopathology. An ante-mortem suspicion of EMPF can be based on clinical symptoms, radiographs, biopsy and PCR for EHV 5 on bronchoalveolar lavage fluid.

This is the first report that describes a case of EMPF in Belgium.

CASE REPORT

History

A 20-year-old French warmblood mare, born and raised in Belgium, was presented to the Faculty of Veterinary Medicine at Ghent University with symptoms of weight loss, anorexia, fever and lethargy during the preceding 2-3 weeks. Prior to presentation at the clinic, blood analysis had revealed anemia and hypoproteinemia. The horse had been treated with antibiotics (cefquinome) and steroids (dexamethasone). This treatment reduced the fever, but the horse remained lethargic. On one occasion, the horse had shown signs of difficulty breathing and a trace of blood at the nostrils was seen by the owner.

The horse had been vaccinated on a yearly basis against influenza and tetanus, but not against EHV. The mare had no history of significant previous illnesses, had not participated in any competitions, and had lived in a private stable with three other horses.

Clinical findings

At the moment of presentation, clinical examination of the horse was unremarkable except for a slight increase in respiration rate (28/min) and poor body condition (weight 454kg).

Auscultation of the lungs at rest revealed increased breath sounds on both sides. An ultrasound of the lungs was performed and showed multiple consolidations on the left and right side of the lung surface (1-3cm diameter). No increased amount of pleural fluid was seen.

A complete blood analysis showed slight anemia (PCV 28%, reference range (rr) 35-45%) and marked hypoproteinemia (protein concentration 45 g/l, rr 60-80 g/l), comparable to the results of the previous blood analysis. Other blood values were within normal limits.

Arterial blood gas analysis revealed a severe hypoxemia (PaO₂: 69.3 mmHg, rr 95-105 mmHg) and normocapnea.

On endoscopy of the upper airways, petechial bleedings were seen in the pharynx and an increased amount of mucus was present in the trachea. Analysis of this mucus revealed a low nucleated cell count consisting predominantly of macrophages. Overnight aerobic culture of this mucus was bacteriologically negative. Bacteriological examination of bronchoalveolar lavage (BAL) fluid was negative and the cytology was moderately cellular, with the presence of mucus strands. The intact cells were mostly vacuolated macrophages with large nuclei and multiple prominent nucleoli. Some macrophages were multinucleated. Fewer segmented neutrophils were present. No inclusion bodies were found.

Thoracic radiography revealed a severe diffuse cloudy increase in opacity of mainly the dorsal and dorso-caudal lung field, obscuring the vasculature and the

bronchial walls. Several ovoid rims of soft tissue opacity were visible throughout the dorsal lung field.

Differential Diagnosis

Based on the clinical signs and the ultrasonographic and radiographic lesions, the differential diagnosis included neoplasia, idiopathic granulomatous pneumonia, bacterial, fungal or parasitic pneumonia, and the recently described equine multinodular pulmonary fibrosis (Williams *et al.*, 2007; Wong *et al.*, 2008). The absence of inflammatory changes in the respiratory secretions and the negative bacteriological cultures made neoplasia, idiopathic granulomatous pneumonia or equine multinodular pulmonary fibrosis more likely.

Biopsy

A lung biopsy was performed under ultrasonographic guidance with a TruCut biopsy needle (Cook® 16G 20mmT 15cm) at the 6th intercostal space after sedation with 0.2ml of detomidine (Detogesic, Fort Dodge, Muurla, Finland) and local anesthesia with 1ml of procaine (Procaïnehydrochloride 4% + adrenaline, Kela nv, Hoogstraten, Belgium).

Histological examination revealed a diffuse severe interstitial fibrosis with infiltration of macrophages and neutrophils. There was marked hyperplasia of the type II pneumocytes and some alveolar lumina contained exudate with mainly degenerated neutrophils. A diagnosis of diffuse severe interstitial pneumonia was made based on the histological lesions.

Treatment and clinical course

A treatment with antibiotics and corticosteroids was started. For a period of 10 days, cefquinome (cobactan 1mg/kg, Intervet, Mechelen, Belgium) was given intramuscularly SID in combination with 2000 mg prednisolon orally SID during the first 2 days. Thereafter the dosage of prednisolone was lowered to 1000mg SID during the next 8 days. Additionally, ipratropium bromide (Atrovent (R) 400mcg, Boehringer Ingelheim, Great-Britain) was given by aerosol TID and acetylcysteine (Lysomucil, Zambon, Brussels, Belgium) 600mg BID was administered orally for 5 days.

During the treatment, intermittent fever was noted, with temperatures fluctuating between 37.6°C and 39.2 °C.

Five days after the start of the treatment, blood gas analysis showed a normal PaO₂ (98.3 mmHg). However, from the 6th day of treatment on, the horse also developed intermittent bouts of mild colic, with reduced fecal passage and mild cecal tympany. Throughout the treatment period, the horse remained anorexic and continued to lose weight.

Ten days after admission, a control x-ray was taken and showed no improvement.

Given the age of the horse, the deterioration of its general condition and the lack of radiographic improvement, the owners decided to have the horse euthanized. A complete necropsy was performed.

Necropsy and histopathology

The liver was moderately enlarged, with random foci of calcification (diameter 1-2mm). Several left para-ovarian cysts were present and severe ulcerative gastritis was found. The most severe changes, however, were present in the lungs. All the lung lobes were affected. The dorsocaudal lung lobes showed the most prominent lesions, as numerous coalescing fibrous nodules were present. These nodules were moderately firm and white. The ventral lung regions showed multifocal nodules with a similar appearance, though smaller in size. The diameter of the individual nodules throughout the lung parenchyma ranged from 1 to 7cm. Approximately 80% of the lung tissue was affected. On cut surface, the fibrous nodules bulged slightly from the surrounding tissue. Furthermore, the retropharyngeal and bronchial lymph nodes were markedly enlarged. The larynx and trachea showed no abnormalities.

Impression smears of lung tissue were moderately cellular. Intact cells were mostly vacuolated macrophages, some multinucleated. Few neutrophils were present. In these impression smears, no inclusion bodies were detected and bacteria or other infectious agents were not observed.

Representative tissue samples of the lungs were fixed in phosphate buffered formalin. After fixation, the samples were routinely embedded in paraffin wax, cut in 5- μ m-thick sections and stained with standard hematoxylin and eosin (HE) and Elastica von Gieson.

Several sections were incubated with a polyclonal rabbit anti-human CD3 (Dakocytomation, Glostrup, Denmark) that labels T-lymphocytes (both helper and cytotoxic T-lymphocytes), a monoclonal mouse anti-human CD79 (clone HM57, Dakocytomation) that labels B-lymphocytes, a monoclonal mouse anti-human HLA-DR α (clone TAL-1B5, Dakocytomation) that labels MHC II positive cells, and a monoclonal mouse antibody anti-MAC387 (Abcam, Cambridge, UK) that labels reactive and tissue macrophages. Significant histologic lesions were restricted to the lungs. The nodules were more or less sharply demarcated from adjacent less affected lung parenchyma. The lesions consisted of diffuse intense interstitial fibrosis with interstitial infiltration of a moderate amount of CD3 positive cells (T-lymphocytes). The alveolar lumina were diffusely lined with cuboidal cells (proliferation of type II pneumocytes) and contained large numbers of vacuolated macrophages (confirmed by MAC 387 staining) and fewer neutrophils. A small number of macrophages contained abundant eosinophilic cytoplasm and a large oval eosinophilic to amphophilic intranuclear inclusion body (Figure 1). The bronchi showed no abnormalities.

Virological examination

The presence of intranuclear inclusion bodies could possibly indicate sites for the presence of viruses such as herpesviruses, so lung tissue was submitted for viral isolation and/or polymerase chain reaction (PCR) as-

says. Virus isolation was performed as previously described (van der Meulen *et al.*; 2003). Briefly, 20% suspensions of lung tissue were titrated on equine embryonic kidney (EEK) cells and the wells were inspected daily for the presence of cytopathic effects. No plaque formation was observed after 7 days of incubation, and therefore the sample was considered negative for EHV 1 and EHV 4. The presence of EHV 1 virus was further investigated by immunohistochemical staining on fixed lung tissue samples. Sections of lung were immunolabeled for EHV 1 antigen with a polyclonal goat antibody against EHV 1 (VHRD, Pullman, Washington, USA) and a commercial kit (Dakocytomation Envision System HRP). Immunohistochemical staining for EHV 1 was negative.

To detect the presence of EHV 2 or EHV 5 genome copies, DNA was extracted from the lung tissue and amplified by PCR, exactly as described elsewhere (Borchers *et al.*, 1999). The lung tissue was negative for EHV 2, but was positive for EHV 5.

DISCUSSION

In this study, we describe the second case of herpesvirus-associated multinodular pulmonary fibrosis in a horse found outside of North America.

In 2007 Williams *et al.* described the first cases of equine multinodular pulmonary fibrosis (EMPF) in horses. Since then, only two additional reports of multinodular pulmonary fibrosis have been published (Wong *et al.*, 2008, Hart *et al.*, 2008), including one horse from the Newmarket area in England (Wong *et al.*, 2008).

On the basis of the gross pathology, we can discern two manifestations of EMPF. The first shows numerous coalescing nodules of fibrosis 1-5cm in diameter. The nodules are pale white and moderately firm. A large portion of the lung is affected. The horse in this case report showed the typical lesions of the first manifestation. The second type of manifestation occurs less fre-

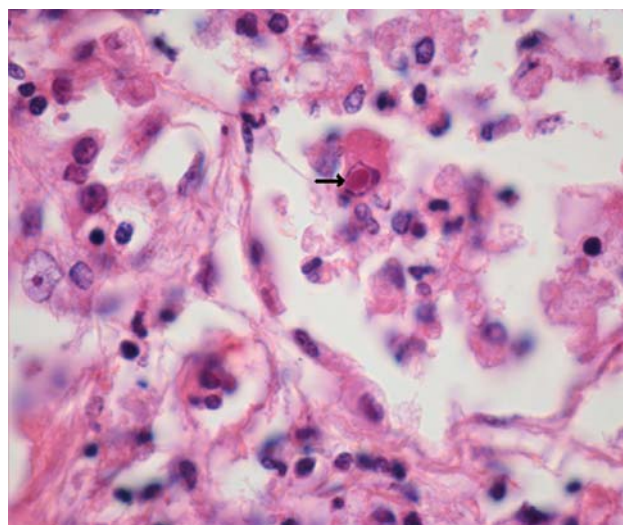


Figure 1. Lung of the mare. Alveolar macrophage with intranuclear presence of herpesvirus inclusion body. HE, 1000x.

quently and is characterized by multiple discrete nodules 10cm in diameter. Grossly unaffected lung is present (Williams *et al.*, 2007).

The histology in both types shows diffuse interstitial fibrosis and alveolar lumina lined by cuboidal cells and filled with several vacuolated macrophages. Some of the macrophages contain large eosinophilic intranuclear inclusion bodies indicative for herpesviruses (Williams *et al.*, 2007; Wong *et al.*, 2008; Hart *et al.*, 2008). The average age of the affected horses was 14.5 years (Williams *et al.*, 2007; Wong *et al.*, 2008), with ages ranging from 4 to 26 years (Williams *et al.*, 2007). The horse in the present case was 20 years old and presented all the typical gross and histologic lesions as described in the previous articles.

EMPF is reported to be associated with EHV 5 (Williams *et al.*, 2007; Hart *et al.*, 2008; Wong *et al.*, 2008). The present case tested positive for EHV 5.

The etiology and pathogenesis of EMPF and, by extension, the role of EHV 5 in this syndrome remain unclear. In all cases of EMPF described so far, EHV 5 is present, but causality has not yet been proven.

EHV 5 has been detected in healthy horses in different parts of the world. Fortier *et al.* (2008) demonstrated the presence of EHV5 by PCR in 19 out of 785 bronchoalveolar and tracheal lavages of French horses. In New Zealand, 38 out of 114 healthy horses tested positive with PCR for EHV 5 (Dunowska, Meer and Wilks, 1999). In Hungary, 15% of the foals tested were positive for EHV 5 by PCR on peripheral blood leucocytes, and in the United Kingdom 24% of a group of 21 ponies tested positive (Nordengrahn *et al.*, 2002). In the US the prevalence of EHV 5 in a group of young race horses was estimated at 64% after a type-specific PCR was used on nasopharyngeal excretions (Bell *et al.*, 2006). EHV 5 has also been detected in Switzerland (Franchini *et al.*, 1997) and Germany (Borchers *et al.*, 1999), but the prevalence numbers are not available. For Belgium, no epidemiological data on the incidence of EHV 5 infections in horses are available.

In some of the reported cases of EMPF, the presence of EHV 2 has been demonstrated by PCR (Hart *et al.*, 2008; Williams *et al.*, 2007). In our case, EHV 2 was not detected. The inconsistent demonstration of EHV 2 probably only reflects the frequent co-infection of horses by EHV 5 and EHV 2 (Torfasen *et al.*, 2008).

The prevalence reports show that EHV 5 can be present in a high number of horses in some countries (e.g. US, Iceland) or in some horse populations. The reason for the difference in prevalence numbers between countries is not completely clear: perhaps different management techniques could have an influence on the prevalence.

Given the relatively high prevalence of EHV 5 and the few clinical cases of EMPF, the causality of EHV 5 in EMPF remains uncertain. Nevertheless there certainly are strong arguments in favor of a primary (or a complicating) role of EHV 5 in the etiology of EMPF. First of all, Williams *et al.* (2007) in their first description of a series of cases detected EHV 5 by PCR in the lesions from all cases and not in the control horses. Se-

condly, EHV 5 has been amplified from all cases of EMPF ever since (Wong *et al.*, 2008; Hart *et al.*, 2008), including the present case.

Chronic proliferative interstitial lung diseases not associated with silicate pneumoconiosis or other known etiologies were described as an idiopathic entity years ago by Buergelt *et al.* (1986). In those cases, however, the lesions did not present the typical multinodular pattern which is so distinctive and characteristic of EMPF. Also, in humans an idiopathic form of chronic pulmonary fibrosis (IPF) is well known. Remarkably, in 97% of human cases of IPF, herpesviral DNA is detected (Tang *et al.*, 2003).

The possible mechanism of fibrosis induction by *herpesviridae* is unknown. In mice, murine gamma-herpesvirus 68 (MuHV4) has been shown to induce fibrosis in the presence of a co-existing underlying factor such as bleomycin (Lok *et al.*, 2002). Additionally, it is known that humans with IPF have a T helper 2 (Th2) pulmonary phenotype, characterized for example by the presence of increased levels of the profibrotic cytokine transforming growth factor (TGF) β and Th2 cytokines, which may ultimately lead to fibrosis and loss of lung function (Wallace *et al.*, 1995). Therefore another hypothesis could be that the cytokine modulatory properties of herpesviruses (Alcami, 2003; Nicolas, 2005) might drive the pulmonary immune system towards a Th2-biased immune response, and hence contribute to the development of chronic pulmonary lung fibrosis. For EHV 5-associated EMPF in horses, no predisposing factors or changes in immune response have been identified to date.

EMPF is a difficult clinical diagnosis. Based on the clinical examination, radiography and ultrasound, EMPF can be suspected (Wong *et al.*, 2008; Hart *et al.*, 2008), but the definite diagnosis of EMPF can only be made post-mortem by necropsy and subsequent histological and virological examination of lung tissue. Demonstrating the presence of EHV 5 in a patient is readily done since PCR can be performed on nasal swabs (Bell *et al.*, 2006; Dunowska, Meers and Wilks, 1999), bronchoalveolar and tracheal lavage fluids (Wong *et al.*, 2008; Fortier *et al.*, 2008) or blood mononuclear cells (Bell *et al.*, 2006; Dunowska, Meers and Wilks 1999). But, since EHV 5 can be present in a high number of healthy horses, the mere identification of EHV 5 in a patient is not conclusive for the diagnosis of EMPF.

Also, in this case there was a suspicion of EMPF based on clinical symptoms in combination with the radiographic and ultrasonographic findings. The lung biopsy in this case did not yield sufficient information for a definite ante-mortem diagnosis. A definite diagnosis was made at necropsy and histology.

This is the first case of EMPF associated with EHV 5 described in Belgium. Further research is necessary to elucidate the pathogenesis of this puzzling disorder and especially to identify the possible role of EHV 5 in the development of lung fibrosis.

REFERENCES

- Alcami A. (2003). Viral mimicry of cytokines, chemokines and their receptors. *Nature Reviews Immunology* 3(1), 36-50.
- Bell S.A., Balasuriya U.B.R., Nordhausen R.W., MacLachlan N.J. (2006). Isolation of equine herpesvirus-5 from blood mononuclear cells of a gelding. *Journal of Veterinary Diagnostic Investigation* 18(5), 472-475.
- Borchers K., Frölich K., Ludwig H. (1999). Detection of equine herpesvirus types 2 and 5 (EHV-2 and EHV-5) in Przewalski's wild horses. *Archives of Virology* 144(4), 771-780.
- Buergelt C.D., Hines S.A., Cantor G., Stirk A., Wilson J.H. (1986). A Retrospective Study of Proliferative Interstitial Lung Disease of Horses in Florida. *Veterinary Pathology* 23(6), 750-756.
- Dunowska M., Meers J., Wilks C.R. (1999). Isolation of equine herpesvirus type 5 in New Zealand. *New Zealand Veterinary Journal* 47(2), 44-46.
- Dunowska M., Holloway S.A., Wilks C.R., Meers J. (2000). Genomic variability of equine herpesvirus-5. *Archives of Virology* 145(7), 1359-1371.
- Fortier G., Pronost S., Miszczak F., Fortier C., Léon A, Richard E., Van Erck E., Thiry E., Lekeux P. (2009). Identification of equid herpesvirus-5 in respiratory liquids: A retrospective study of 785 samples taken in 2006-2007. *The Veterinary Journal* 182(2), 346-348.
- Franchini M., Akens M., Bracher V., von Fellenberg R. (1997). Characterisation of gamma herpesviruses in the horse by PCR. *Virology* 238(1), 8-13.
- Hart K.A., Barton M.H., Williams K.J., Flaminio M.J.B.F., Howerth E.W. (2008). Multinodular pulmonary fibrosis, pancytopenia and equine herpesvirus-5 infection in a Thoroughbred gelding. *Equine Veterinary Education* 20(9), 470-476.
- Lok S.S., Egan J.J. (2000). Viruses and idiopathic pulmonary fibrosis. *Monaldi Archives for Chest Disease* 55(2), 146-150.
- Lok S.S., Haider Y., Howell D., Stewart J.P., Hasleton P.S., Egan J.J. (2002). Murine gammaherpes virus as a cofactor in the development of pulmonary fibrosis in bleomycin resistant mice. *European Respiratory Journal* 20(5), 1228-1232.
- Nicholas J. (2005). Human gammaherpesvirus cytokines and chemokine receptors. *Journal of Interferon and Cytokine Research* 25(7), 373-383.
- Nordengrahn A., Merza M., Ros C, Lindholm A., Palfl V., Hannant D., Belák S. (2002). Prevalence of equine herpesvirus types 2 and 5 in horse populations by using type-specific PCR assays. *Veterinary Research* 33(3), 251-259.
- Tang Y.W., Johnson J.E., Browning P.J., Cruz-Gervis R.A., Davis A., Graham B.S., Brigham K.L., Oates J.A. Jr, Loyd J.E., Stecenko A.A. (2003). Herpesvirus DNA is consistently detected in lungs of patients with idiopathic pulmonary fibrosis. *Journal of Clinical Microbiology* 41(6), 2633-2640.
- Torfason E.G., Thorsteinsdottir L., Torsteinsdottir S., Svansson V. (2008). Study of equid herpesviruses 2 and 5 in Iceland with a type-specific polymerase chain reaction. *Research in Veterinary Science* 85(3), 605-611.
- van der Meulen K., Vercauteren G., Nauwynck H., Pensaert M. (2003). A Local Epidemic of Equine Herpesvirus 1- Induced Neurological Disorders in Belgium. *Vlaams Diergeneeskundig Tijdschrift* 72, 366-372.
- Wallace W.A., Ramage E.A., Lamb D., Howie S.E. (1995). A type 2 (Th2-like) pattern of immune response predominates in the pulmonary interstitium of patients with cryptogenic fibrosing alveolitis (CFA). *Clinical and Experimental Immunology* 101(3), 436-441.
- Williams K.J., Maes R., Del Piero F., Lim A., Wise A., Bolin D.C., Caswell J., Jackson C., Robinson N.E., Derksen F., Scott M.A., Uhal B.D., Li X., Youssef S.A., Bolin S.R. (2007). Equine multinodular pulmonary fibrosis: a newly recognized herpesvirus-associated fibrotic lung disease. *Veterinary Pathology* 44(6), 849-862.
- Wong D.M., Belgrave R.L., Williams K.J., Del Piero F., Alcott C.J., Bolin S.R., Marr C.M., Nolen-Walston R., Myers R.K., Wilkins P.A. (2008). Multinodular pulmonary fibrosis in five horses. *Journal of the American Veterinary Medical Association* 232(6), 898-904.