

## Equine sarcoids – Part 2: current treatment modalities

### *Equine sarcoïden – Deel 2: huidige behandelingsmogelijkheden*

L. Bogaert, A. Martens, P. Depoorter, F. Gasthuys

Department of Surgery and Anesthesiology of Domestic Animals, Faculty of Veterinary Medicine, Ghent University, Salisburylaan 133, B-9820 Merelbeke, Belgium

lies.bogaert@UGent.be

#### ABSTRACT

Treatment of sarcoids is often challenging, due to the variable clinical presentation of lesions and the frequent local recurrences. In this article, both the surgical and the non-surgical treatment of equine sarcoids are reviewed. It is generally accepted that the prognosis is worse if unsuccessful attempts have been made previously. Therefore, the best available treatment option should always be used at the first attempt of treatment. Different surgical approaches have been reported, including conventional excision, cryosurgery and CO<sub>2</sub> laser surgery. Success rates are high if a non-touch approach, wide surgical margins and general anesthesia can be applied. Local chemotherapy is a valuable addition in the treatment of sarcoids and can be combined with surgery. Radiotherapy is a very successful treatment, but safety precautions prevent routine application. Local immunotherapy including Bacillus Calmette-Guérin vaccination and imiquimod cream are commonly applied treatments which induce rather effective tumour regression.

#### SAMENVATTING

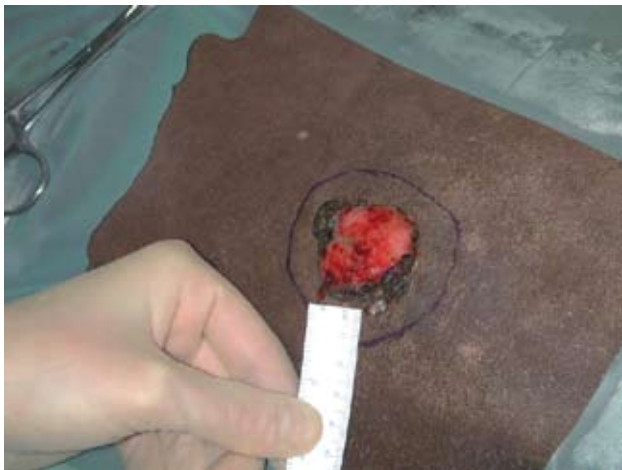
De behandeling van sarcoïden is vaak een uitdaging door het variabel klinisch gedrag en het frequent optreden van lokale recidieven. In dit artikel wordt een overzicht gegeven van zowel de chirurgische als niet-chirurgische behandeling van equine sarcoïden. Algemeen wordt aangenomen dat de prognose slechter wordt indien een eerdere behandeling vruchteloos bleek. Daarom is het van belang om bij de behandeling onmiddellijk de best mogelijke optie aan te wenden. Verschillende chirurgische benaderingen worden beschreven, waaronder de conventionele excisie, cryochirurgie en CO<sub>2</sub>-laserbehandeling. Het slagingspercentage is hoog indien een "non-touch" benadering, de wegname van brede randen normale huid en een algemene anesthesie worden toegepast. Lokale chemotherapie is een waardevolle aanvulling bij de behandeling van sarcoïden en kan gecombineerd worden met chirurgie. Bestraling is een andere succesvolle behandeling, maar strenge veiligheidsmaatregelen belemmeren een routinematige toepassing ervan. Lokale immunotherapieën, zoals de vaccinatie met Bacillus Calmette-Guérin en imiquimod crème, worden regelmatig toegepast en resulteren in behoorlijk goede tumorregressie.

#### INTRODUCTION

The treatment of equine sarcoids has always been challenging, due to the variable clinical presentation of lesions and the frequent local recurrences. Therefore, careful selection of the appropriate treatment for each sarcoid and each horse should be made, taking into account the localization, number and size of the tumors, the treatment history, the financial value of the animal and the owner compliance to fulfil the treatment schedule (Marti *et al.*, 1993; Carstanjen and Lepage, 1998).

Both surgical and non-surgical techniques have been described with variable success rates. Since none of the current techniques has been proven to be 100 % successful (Marti *et al.*, 1993), the confidence of owners in conventional treatments may decrease, leading them to use a whole scale of topical ointments (including toothpaste), homeopathy,... Despite the lack of any scientific evidence, tumor regression

can occasionally be seen after these alternative therapies. Cure, however, may also be a result of spontaneous regression, which is observed in up to 32 % of the cases (Brostrom, 1995; Martens *et al.*, 2001b). Therefore, benign neglect can be an option, especially in case of small tumors (Knottenbelt *et al.*, 1995; Pascoe and Knottenbelt, 1999). Careful monitoring is yet very important, since aggravation can happen anytime without an obvious reason. It should be kept in mind that not all horses with equine sarcoids can be cured: in horses with a very large number of sarcoids, or with sarcoids with a very large surface, treatment may be impossible. Even in case of a small single sarcoid owners should be warned about possible local recurrence and deterioration of the sarcoid (Knottenbelt *et al.*, 1995; Carstanjen and Lepage, 1998). Moreover, the development of new sarcoids on other locations is always possible (Brostrom, 1995; Carstanjen *et al.*, 1997; Carstanjen and Lepage, 1998). It is generally accepted that the prognosis



**Figure 1.** Demarcation of a normal skin margin of 12 mm to perform excision of a fibroblastic sarcoid.

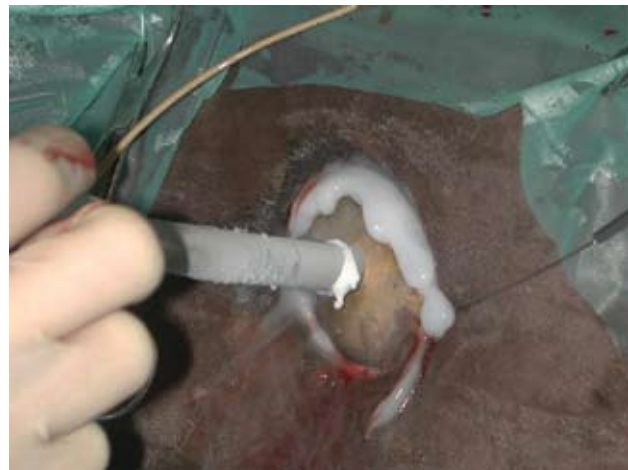for treatment is significantly worse if one or more unsuccessful attempts have been made previously (Knottenbelt and Walker, 1994). Therefore, the best available treatment option with the highest chance of success should always be used at the first attempt of treatment (Pascoe and Knottenbelt, 1999).

In this paper, only the most commonly applied treatments in equine practice will be presented. Treatments with only anecdotic evidence, such as *Sanguinaria canadensis* (XXTerra®), photodynamic therapy, homeopathy, acupuncture, ligation, hyperthermia and various topical ointments will not be discussed further (Hoffman *et al.*, 1983; Schwierczna, 1993; Brostrom, 1995; Thoresen, 1995; Pascoe and Knottenbelt, 1999; Martens *et al.*, 2000; von Felbert *et al.*, 2005).

## SURGICAL TREATMENT

### Conventional excision

Surgical excision of equine sarcoids has been applied for decades with variable success. High recurrence rates of 40 to 72 % are reported (Ragland, 1970; Diehl *et al.*, 1987; Mcconaghy *et al.*, 1994; Brostrom, 1995). This can be attributed to the infiltrative nature of the tumor and auto-transplantation of tumor cells during the surgical procedure (Klein, 1990; Howart, 1990). On histology, fronds of tumor cells infiltrating the surrounding dermis and sometimes the underlying tissues can be observed (Ragland, 1970; Tarwid *et al.*, 1985). The detection of BPV DNA at the surgical margin of an excised sarcoid correlates with an increased risk of recurrence (Martens *et al.*, 2001a). When the excision is performed with wide normal skin margins (at least 12 mm; Figure 1) and a non-touch approach (i.e. changing of gloves and material after tumor removal and extensive flushing of the wound), auto-inoculation with tumor cells and viral material can be avoided and success rates of more than 80 % are achieved (Howart, 1990; Brostrom, 1995; Martens *et al.*, 2001b). Another major factor in the prognosis is the possibility to perform the excision under general anesthesia (80 % success) compared to



**Figure 2.** Continuous circulation contact probes for cryosurgery of debulked sarcoid lesions. Tissue temperature is monitored carefully with thermocouple needles inserted into the tumor mass.

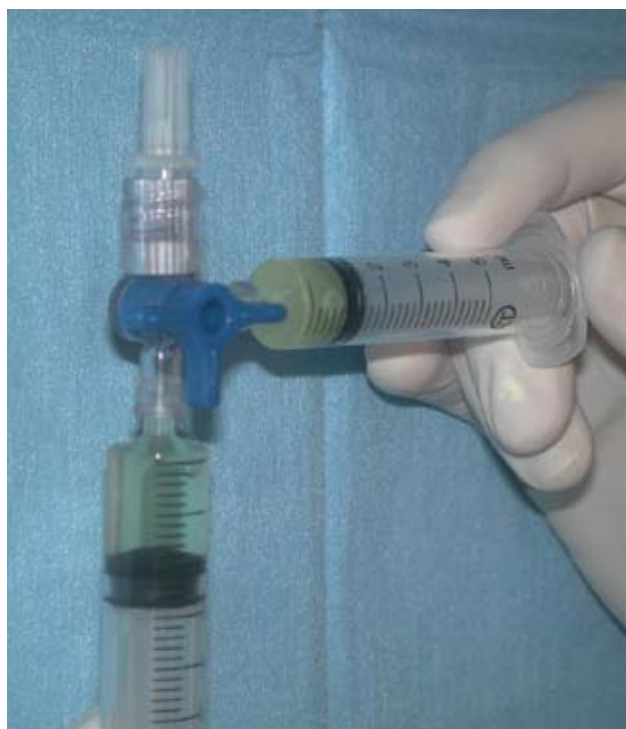working on the standing horse (24 % success). General anesthesia provides the surgeon a clear view on the sarcoids, a good ability to remove wide margins and creates good conditions to avoid auto-inoculation (Brostrom, 1995).

### CO<sub>2</sub> laser surgery

Excision with the CO<sub>2</sub> laser is an efficient tool for the treatment of equine sarcoids. Success rates range from 60 to 89 % (Diehl *et al.*, 1987; Vingerhoets *et al.*, 1988; Carstanjen *et al.*, 1997; Martens *et al.*, 2001b). Large masses are commonly laser-excised using the same approach as described for the conventional excision. Small or flat lesions can be entirely vaporized with the CO<sub>2</sub> laser (Diehl *et al.*, 1987; Vingerhoets *et al.*, 1988; Carstanjen *et al.*, 1997; Weigand *et al.*, 1997). Laser ablation causes less damage to the surrounding tissues and less spread of malignant cells to healthy regions compared to sharp surgical excision with mechanical tools (Carr, 2006). However, poor cosmetic results including scar tissue formation, alopecia, leucotrichia and transient abnormal hair color can sometimes be observed (Vingerhoets *et al.*, 1988; Carstanjen *et al.*, 1997). Other drawbacks are the cost of the equipment and the required safety precautions against burns, fire, eye damage and smoke inhalation (Palmer, 1989).

### Cryosurgery

Both in human and veterinary medicine cryosurgery has become an accepted way of treating malignancies. Cell death is obtained by repeated freeze-thaw cycles, with optimal cryonecrosis achieved by rapid freezing and slow thawing of the tissue (Farris *et al.*, 1976; Fretz and Barber, 1980). Prior to freezing, large sarcoid masses are debulked to the level of the surrounding skin or even lower, followed by freezing of the tumor base and a normal skin margin with liquid nitrogen (Figure 2). Tissue should be frozen to at least -20 to -25 °C. Temperature control is essential and can be obtained with thermocouple needles (Farris *et al.*, 1976). After the procedure, a black lea-



**Figure 3.** Preparation of cisplatin emulsion by mixing of an aqueous cisplatin solution and sesame oil through a 3-way valve.

they crust develops within a few days, and sloughs gradually over several weeks eventually leading to an open wound which heals by second intention.

Success rates vary from 60 to 100 % (Lane, 1977; Fretz and Barber, 1980; Klein *et al.*, 1986; Diehl *et al.*, 1987; Martens *et al.*, 2001b). Occasionally, spontaneous regression of non-treated sarcoids on the same horse can be observed, indicating that destruction of one tumor can result in an immune response against other, distant sarcoids (Lane, 1977). Disadvantages of the technique are the prolonged anesthesia time required, the cosmetic effects (scarring, leucodermia, leucotrichia) and the possible damaging of underlying structures. The latter makes cryosurgery less suitable for periocular sarcoids or tumors located on large vessels, nerves, ligaments or joints, unless careful temperature control with thermocouples is performed (Lane, 1977; Fretz and Barber, 1980; Mcconaghy *et al.*, 1994; Knottenbelt *et al.*, 1995).

## NON-SURGICAL TREATMENT

### Chemotherapy

Administration of cytotoxic drugs results in tumor cell death and can be performed in two ways: systemically and locally. Local chemotherapy can be applied intralesionally or topically. The rationale for local chemotherapy is based on achieving a high drug concentration over time in the tumor while sparing normal tissue. The general circulation is bypassed and a low systemic exposure is obtained, thereby minimizing toxicity (Theon, 1998). Due to its cutaneous localization, sarcoids are most convenient for local chemotherapy.

Intralesional injection of cytotoxic drugs directly

into the tumor allows higher intratumoral drug concentrations and permits accurate placement of the drug within the tumor (Theon, 1998; Mair and Couto, 2006). The beneficial effects are enhanced if drug carriers that prolong the persistence of the drug in the tumor are used. Viscous fluid preparations such as sesame seed or almond oil are frequently used to achieve this effect (Theon *et al.*, 1993). The most widely used drug in this manner is cisplatin with a 2-year local control rate of approximately 90 % (Theon *et al.*, 1993; Theon *et al.*, 1994; Theon, 1998). Intralesional cisplatin can be effective as the sole treatment for small sarcoids, but for large tumors the combined use with surgery is recommended (Theon *et al.*, 1994; Theon, 1998). Local cisplatin injected at the time of surgical sarcoid excision was shown not to have any adverse effect on wound healing (Theon *et al.*, 1994). Emulsions are made up from 1 ml of an aqueous solution of 10 mg cisplatin and 2 ml sesame oil and are mixed using 2 syringes and a 3-way valve (Figure 3). A dose rate of 1 mg cisplatin/cm<sup>3</sup> of tumor can be applied. The sarcoid as well as a margin of normal skin of 1-2 cm should be injected using a parallel-row or field-block technique (Theon *et al.*, 1997). A standard treatment protocol includes 4 injections at 2-week intervals. Side effects of treatment are strictly local (inflammation, swelling, focal ulceration) and self-limiting (Theon, 1998). Prophylactic antibiotic therapy and anti-inflammatory drugs are recommended after each treatment session to prevent acute clostridial infection. The cosmetic and functional results are excellent (Theon, 1998). Alternative cisplatin formulations with almond oil or epinephrine as well as local chemotherapy with bleomycin and 5-fluorouracil (5-FU) are described but appear to be less effective (Bouré *et al.*, 1991; Doyle, 1998; Knottenbelt and Kelly, 2000; Stewart *et al.*, 2006).

Topical chemotherapy has been used for over 100 years to treat equine sarcoids. However, the effect of only a few of these drugs has been studied scientifically. 5-FU can be applied as a cream for single, small occult or verrucous sarcoids but also for larger areas of occult or verrucous sarcoids that are not amenable to any other form of treatment. Due to poor diffusion and inadequate distribution from the surface to the deep margins, the use of 5-FU should be limited to flat lesions (Theon, 1998). Topical 5-FU needs to be applied daily for 30-90 days. Alternatively, it can be applied less frequently under a bandage (Roberts, 1970). A success rate of 66 % was observed (Knottenbelt and Kelly, 2000). To aid the penetration through the epidermis, 5-FU can be mixed with podophylin, an irritant cathartic (Mcconaghy *et al.*, 1994; Piscopo, 1999). The treated area can show a marked inflammatory reaction, but scarring is usually minimal (Pascoe and Knottenbelt, 1999). Unlicensed topical ointments (AW-3-LUDES and AW-4-LUDES) containing a variety of heavy metals with 5-FU and thiouracil can be applied on successive or alternate days for 3 to 5 treatments, depending on the size, number and nature of the sarcoids (Knottenbelt and Walker, 1994; Knottenbelt and Kelly, 2000). This treatment may cause severe local irritation and scar contracture but a resolution rate of 80 % has been reported in sarcoids being treated for the first time

(Knottenbelt and Walker, 1994). The success rate decreases by 30 to 40% for each previous unsuccessful treatment.

### Radiotherapy

Radiotherapy induces tumor destruction by ionizing radiation. The most frequently used radiotherapeutic method in horses is interstitial brachytherapy with iridium-192 reporting one- and five-year progression-free survival rates of 87 and 74 % respectively for non-ocular sarcoids and 98-100 % for periocular sarcoids (Wyn-Jones, 1983; Turrel *et al.*, 1985; Theon and Pascoe, 1995; Knottenbelt and Kelly, 2000; Byam-Cook *et al.*, 2006). It involves the implantation of sealed radioactive sources within the tissue to treat the tumor at short source-object distances. Because of the long half-life of iridium-192 (74.2 days), the implants are removed once the required dose has been administered, usually after 5 to 6 days. The primary advantage is that high radiation doses can be given directly into the tumor with minimal damage to the surrounding tissues (Henson and Dobson, 2004). The technique is very suitable for tumors on locations where surgical excision is not possible (eyelids, commissure of lips) and good results have been obtained for recurrent sarcoids. Local complications such as necrosis and infection and minor cosmetic defaults (leucotrichia, alopecia, minimal scarring) have been observed (Turrel *et al.*, 1985; Theon and Pascoe, 1995; Theon, 1998; Byam-Cook *et al.*, 2006). A major drawback of this otherwise valuable treatment is the safety of the operators and the need for patient isolation (Wyn-Jones, 1979; Walker *et al.*, 1991).

### Immunotherapy

The purpose of immunotherapy is to enhance the ability of the host to reject the tumor. Antitumoural effects are produced primarily through enhanced immunologic activity. Many immunostimulants have been evaluated in horses, including Bacillus Calmette-Guérin (BCG) vaccine, autovaccination and imiquimod 5 % cream.

BCG is an attenuated strain of *Mycobacterium bovis* originally developed as a tuberculosis vaccine in man and is currently still in use for intravesical treatment of superficial bladder cancer (Brake *et al.*, 2000). Live organisms, dead organisms and cell wall extracts have been used in combination with various adjuvants for intratumoral injection of equine sarcoids. Tumor regression involves both non-specific and specific mechanisms and is based on a delayed hypersensitivity reaction (Morton and Barth, 1995). BCG vaccination consists of multiple injections into the tumor mass and tumor bed to ensure complete infiltration of the target volume. Most commonly 4 injections at a 2-3 week interval are performed. The success rate ranges from 60-100 % and is mainly dependent on tumor size and localization (Klein *et al.*, 1986). Periocular sarcoids are most responsive to treatment with local control rates up to 100 %. Sarcoids on the limbs respond poorly and vaccination can result in massive oedema formation,

lymphangitis or even septic arthritis (Klein *et al.*, 1986; Owen and Jagger, 1987; Theon, 1998). Cytoreductive surgery prior to treatment of bulky tumors is recommended (Theon, 1998). General (anaphylactic shock, death, fever) and local (oedema, purulent discharge, ulceration) side effects have been described and therefore administration of non-steroidal or steroidal anti-inflammatory drugs is recommended prior to BCG vaccination (Theon, 1998).

Autogenous vaccination of sarcoids has been performed with variable success rates. Although promising results of autovaccination combined with food supplements have been reported (Kinnunen *et al.*, 1999), other authors have reported worsening of the condition or new sarcoid development after autovaccination (Knottenbelt *et al.*, 1995; Pascoe and Knottenbelt, 1999).

Imiquimod (Aldara™) is an immune response modifier with potent antiviral and antitumoral activity showing promising results for the treatment of equine sarcoids. Successful treatment of human anogenital warts, actinic keratosis and superficial basal cell carcinoma has been reported (Beutner *et al.*, 1998; Marks *et al.*, 2001; Salasche *et al.*, 2002). Recent studies have shown good results for the treatment of equine sarcoids (Nogueira *et al.*, 2006; own unpublished results). Treatment consists of application of a thin layer of cream on the tumor surface 3 times a week during several weeks to months. In one study, 60 % of the treated sarcoids resolved entirely and another 20 % showed more than 75 % reduction, most of them being recurrences after previous treatment (Nogueira *et al.*, 2006). Local side effects, such as ulceration, pain and depigmentation are often observed.

### LITERATURE

- Beutner K., Edwards L., Owens M., Fox T. (1998). Comparison of two vehicle-controlled trials of imiquimod 5% cream for the treatment of external genital warts. *Journal of Investigative Dermatology* 110, 682-682.
- Bouré L., Krawiecki J.-M., Thoulon F. (1991). Essai de traitement des sarcoïdes du cheval par injection intratumorales de bléomycine (DCI). *Le Point Vétérinaire* 23, 91-96.
- Brake M., Loertzer H., Horsch R., Keller H. (2000). Recurrence and progression of stage T1, grade 3 transitional cell carcinoma of the bladder following intravesical immunotherapy with bacillus Calmette-Guérin. *Journal of Urology* 163, 1697-1701.
- Brostrom H. (1995). A clinical and epidemiologic study in relation to equine leukocyte antigens (ELA). *Acta Veterinaria Scandinavica* 36, 223-236.
- Byam-Cook K.L., Henson F.M.D., Slater J.D. (2006). Treatment of periocular and non-ocular sarcoids in 18 horses by interstitial brachytherapy with iridium-192. *The Veterinary Record* 159, 337-341.
- Carr E.A. (2006). Skin conditions amenable to surgery. In: Auer M. and Stick (editors). *Equine Surgery*. Saunders, St. Louis, p. 309-320.
- Carstanjen B., Jordan P., Lepage O.M. (1997). Carbon dioxide laser as a surgical instrument for sarcoid therapy - A retrospective study on 60 cases. *Canadian Veterinary Journal-Revue Vétérinaire Canadienne* 38, 773-776.

- Carstanjen B., Lepage O.M. (1998). Equine sarcoid (part II): Treatment regimes and prognosis. *Der Praktische Tierarzt* 79, 730-742.
- Diehl M., Vingerhoets M., Stornetta D. (1987). Spezifische Methoden zur Entfernung des Equine Sarkoides. *Der Praktische Tierarzt, Collegium Veterinarium* 18, 14-16.
- Doyle P.S. (1998). Chemotherapeutic modulation of skin tumors. In: White N.A. and Moore J.N. (editors). *Current Techniques in Equine Surgery and Lameness*. 2nd Edition, W.B. Saunders Co., Philadelphia, p. 93-97.
- Farris H.E., Fraunfelder F.T., Mason C.T. (1976). Cryotherapy of equine sarcoid and other lesions. *Veterinary Medicine and Small Animal Clinician* 71, 325-329.
- Fretz P.B., Barber S.M. (1980). Prospective analysis of cryosurgery as the sole treatment for equine sarcoids. *Veterinary Clinics of North America-Small Animal Practice* 10, 847-859.
- Henson F.M.D., Dobson J.M. (2004). Use of radiation therapy in the treatment of equine neoplasia. *Equine Veterinary Education* 16, 315-318.
- Hoffman K.D., Keinder R.A., Shideler R.K. (1983). Radio-frequency current-induced hyperthermia for the treatment of equine sarcoid. *Equine Practice* 5, 24-31.
- Howart S. (1990). Sarcoids: the story so far. *Veterinary Annual* 30, 145-154.
- Kinnunen R.E., Tallberg T., Stenback H., Sarna S. (1999). Equine sarcoid tumour treated by autogenous tumour vaccine. *Anticancer Research* 19, 3367-3374.
- Klein W.R. (1990). Immunotherapy in squamous-cell carcinomas in the bovine eye and equine sarcoids. *Tijdschrift Voor Diergeneeskunde* 115, 1149-1155.
- Klein W.R., Bras G.E., Misdorp W., Steerenberg P.A., Dejong W.H., Tiesjema R.H., Kersjes A.W., Ruitenbergh E.J. (1986). Equine sarcoid - BCG immunotherapy compared to cryosurgery in a prospective randomized clinical-trial. *Cancer Immunology Immunotherapy* 21, 133-140.
- Knottenbelt D.C., Edwards S., Daniel E. (1995). Diagnosis and treatment of the equine sarcoid. *In Practice* 17, 123-129.
- Knottenbelt D.C., Kelly D.F. (2000). The diagnosis and treatment of periorbital sarcoid in the horse: 445 cases from 1974-1999. *Veterinary Ophthalmology* 3, 169-191.
- Knottenbelt D.C., Walker J.A. (1994). Topical treatment of the equine sarcoid. *Equine Veterinary Education* 6, 72-75.
- Lane J.G. (1977). The treatment of equine sarcoids by cryosurgery. *Equine Veterinary Journal* 9, 127-133.
- Mair T.S., Couto C.G. (2006). The use of cytotoxic drugs in equine practice. *Equine Veterinary Education* 18, 149-156.
- Marks R., Gebauer K., Shumack S., Amies M., Bryden J., Fox T.L., Owens M.L. (2001). Imiquimod 5% cream in the treatment of superficial basal cell carcinoma: results of a multicenter 6-week dose-response trial. *Journal of the American Academy of Dermatology* 44, 807-813.
- Martens A., De Moor A., Demeulemeester J., Peelman L. (2001a). Polymerase chain reaction analysis of the surgical margins of equine sarcoids for bovine papilloma virus DNA. *Veterinary Surgery* 30, 460-467.
- Martens A., De Moor A., Vlamincck L., Pille F., Steenhaut M. (2001b). Evaluation of excision, cryosurgery and local BCG vaccination for the treatment of equine sarcoids. *The Veterinary Record* 149, 665-669.
- Martens A., De Moor A., Waelkens E., Merlevede W., De Witte P. (2000). In vitro and in vivo evaluation of hypericin for photodynamic therapy of equine sarcoids. *Veterinary Journal* 159, 77-84.
- Marti E., Lazary S., Antczak D.F., Gerber H. (1993). Report of the 1st International Workshop on Equine Sarcoid. *Equine Veterinary Journal* 25, 397-407.
- McConaghy F.F., Davis R.E., Reppas G.P., Rawlinson R.J., McClintock S.A., Hutchins D.R., Hodgson D.R. (1994). Management of equine sarcoids - 1975-93. *New Zealand Veterinary Journal* 42, 180-184.
- Morton D.L., Barth A. (1995). Local therapy with biologic agents. In: DeVita V.T., Hellman S., and Rosenberg S.A. (editors). *Biologic Therapy of Cancer*. 2nd ed., JB Lippincott, Philadelphia, p. 691-
- Nogueira S.A.F., Torres S.M.F., Malone E.D., Diaz S.F., Jessen C., Gilbert S. (2006). Efficacy of imiquimod 5% cream in the treatment of equine sarcoids: a pilot study. *Veterinary Dermatology* 17, 259-265.
- Owen R.A.R., Jagger D.W. (1987). Clinical Observations on the use of bcg cell-wall fraction for treatment of periorbital and other equine sarcoids. *The Veterinary Record* 120, 548-552.
- Palmer S.E. (1989). Clinical use of a carbon dioxide laser in an equine general surgery practice. In: *Proceedings of the American Association of Equine Practitioners* 319-329.
- Pascoe R.R., Knottenbelt D.C. (1999). Neoplastic conditions. In: Pascoe R.R. and Knottenbelt D.C. (editors). *Manual of Equine Dermatology*. Saunders, London, p. 244-252.
- Piscopo S.E. (1999). The complexities of sarcoid tumors. *Equine Practice* 21, 14-18.
- Ragland W.L. (1970). Equine sarcoid. *Equine Veterinary Journal* 2, 2-11.
- Roberts W.D. (1970). Experimental treatment of equine sarcoid. *Veterinary Medicine, Small Animal Clinician* 65, 67-73.
- Salasche S.J., Levine N., Morrison L. (2002). Cycle therapy of actinic keratoses of the face and scalp with 5% topical imiquimod cream: an open-label trial. *Journal of the American Academy of Dermatology* 47, 571-577.
- Schwierczena J. (1993). Behandlung des equinen Sarcoids mit homoöpathischen Arzneimitteln. *Biologische Tiermedizin* 3, 78-82.
- Stewart A.A., Rush B., Davis E. (2006). The efficacy of intratumoural 5-fluorouracil for the treatment of equine sarcoids. *Australian Veterinary Journal* 84, 101-106.
- Tarwid J.N., Fretz P.B., Clark E.G. (1985). Equine sarcoids - A study with emphasis on pathologic diagnosis. *Compendium on Continuing Education for the Practicing Veterinarian* 7, S293-S300.
- Theon A.P. (1998). Intralesional and topical chemotherapy and immunotherapy. *Veterinary Clinics of North America-Equine Practice* 14, 659-671.
- Theon A.P., Pascoe J.R. (1995). Ir-192 Interstitial brachytherapy for equine periorbital tumors - treatment results and prognostic factors in 115 horses. *Equine Veterinary Journal* 27, 117-121.
- Theon A.P., Pascoe J.R., Carlson G.P., Krag D.N. (1993). Intratumoral chemotherapy with cisplatin in oily emulsion in horses. *Journal of the American Veterinary Medical Association* 202, 261-267.
- Theon A.P., Pascoe J.R., Madigan J.E., Carlson G., Metzger L. (1997). Comparison of intratumoral administration of cisplatin versus bleomycin for treatment of

- periocular squamous cell carcinomas in horses. *American Journal of Veterinary Research* 58, 431-436.
- Theon A.P., Pascoe J.R., Meagher D.M. (1994). Perioperative intratumoral administration of cisplatin for treatment of cutaneous tumors in equidae. *Journal of the American Veterinary Medical Association* 205, 1170-1176.
- Thoresen A. (1995). Akupunkturbehandling av equint sarkoid. *Norsk Veterinaertidsskrift* 10, 963-964.
- Turrel J.M., Stover S.M., Gyorgyfalvy J. (1985). Ir-192 Interstitial brachytherapy of equine sarcoid. *Veterinary Radiology* 26, 20-24.
- Vingerhoets M., Diehl M., Gerber H., Stornetta D., Rausis C. (1988). Treatment of equine sarcoid by CO<sub>2</sub>-laser. *Schweizer Archiv für Tierheilkunde* 130, 113-126.
- von Felbert I., Dreschel W., Teifke J.P. (2005). Regression of an equine sarcoid after treatment with a compound of Sanguinad canadensis - a case report. *Der Praktische Tierarzt* 86, 330-334.
- Walker M., Adams W., Hoskinson J., Held J.P., Blackford J., Geiser D., Goble D., Henton J. (1991). Ir-192 brachytherapy for equine sarcoid, one and 2 year remission rates. *Veterinary Radiology* 32, 206-208.
- Weigand K., Gerhards H., Kostlin R. (1997). The application of laser assisted surgery in veterinary medicine 3. The use of laser surgery in veterinary medicine. *Tierärztliche Praxis* 25, 289-302.
- Wyn-Jones G. (1983). Treatment of equine cutaneous neoplasia by radiotherapy using iridium 192 linear sources. *Equine Veterinary Journal* 15, 361-365.
- Wyn-Jones G. (1979). Treatment of periocular tumours of horses using radioactive gold-198 grains. *Equine Veterinary Journal* 11, 3-10.

## OPROEP

### Onderzoek naar equine sarcoïd

Op de Vakgroep Heelkunde en Anesthesie van de Huisdieren van de Faculteit Diergeneeskunde te Merelbeke loopt momenteel een onderzoek naar de transmissie van het boviene papillomavirus. Hiervoor zijn we op zoek naar proefpaarden met equine sarcoïden, evenals naar paarden die vroeger reeds behandeld werden voor sarcoïden maar nu sarcoïd-vrij zijn. Deze paarden zullen gebruikt worden om de exacte manier van transmissie te ontzamen, uitgaande van viraal materiaal afkomstig van zowel runderen als van paarden. Opgelet: deze paarden zullen worden overgekocht door de vakgroep en kunnen dus niet in het bezit blijven van de eigenaar! Indien u in uw cliënteel dergelijke dieren hebt die anders toch moeten geëuthanaseerd of geslacht worden, kunt u ons steeds contacteren voor overname van deze dieren.

Contact: Pieter Depoorter (pieter.depoorter@UGent.be), Lies Bogaert (lies.bogaert@UGent.be)




# Vita-Vitaal




## extra gezond resultaat!

Vita-Vitaal is een jonge, snelgroeiende organisatie, gericht op de grote veehouderijbedrijven. Wij beheren een aantal specifieke voedingsproducten met internationale impact. Voor onze solide, technische productondersteuning zijn wij op zoek naar een enthousiaste en ondernemende

### Dierenarts

werkgebied Brabant-Limburg

Binnen ons team past een praktisch ingestelde (ervaren) persoonlijkheid met uitstekende communicatieve vaardigheden. Uw kennis is voornamelijk gericht op diergezondheidsaspecten in de varkenshouderij. Voedingskundige know how kunnen wij uiterst nauwgezet aanvullen, waardoor uw specialiteiten diergezondheid, voeding en zoötechniek optimaal tot hun recht komen. Vita-Vitaal biedt de juiste kandidaat een uiterst boeiende en zelfstandige functie. U onderhoudt waardevolle contacten met veehouders in de intensieve veehouderij, studieclubs en collega's. Tevens neemt u zitting in ons managementteam. Onze primaire en secundaire arbeidsvoorwaarden zijn solide en bijzonder goed te noemen.

Belangstellenden kunnen hun schriftelijke sollicitatie binnen 21 dagen richten aan: Vita-Vitaal, t.a.v. de heer drs. R. Fourier, postbus 21, 6114 ZG Susteren. U kunt ook per e-mail reageren: [info@vita-vitaal.nl](mailto:info@vita-vitaal.nl). Telefonische informatie betreffende deze vacature kunt u verkrijgen bij de heer drs. R. Fourier, (Managing Director and Technical Support), tel: +32 495201478.