

## Torsion of the spermatic cord in a Warmblood stallion

### *Torsie van de zaadstreng bij een warmbloed hengst*

<sup>1</sup>M. De Bock, <sup>1</sup>J. Govaere, <sup>2</sup>A. Martens, <sup>1</sup>M. Hoogewijs, <sup>1</sup>C. De Schauwer, <sup>1</sup>K. Van Damme, <sup>1</sup>A. de Kruif

<sup>1</sup>Department of Reproduction, Obstetrics and Herd Health

<sup>2</sup> Department of Surgery and Anesthesiology of Domestic Animals

Faculty of Veterinary Medicine, Ghent University, Salisburylaan 133, B-9820 Belgium

jan.govaere@Ugent.be

#### ABSTRACT

In this case report, a 720 degree torsion of the spermatic cord in a 2.5-year-old Warmblood stallion is described. Diagnosis was made through palpation and ultrasonography, and since future breeding potential was not important, a bilateral orchidectomy was performed. The main pathology of testicular torsion is ischemia and reperfusion injury of the testis. Several antioxidant agents such as allopurinol and melatonin could be effective in preventing testicular ischemia and reperfusion injury.

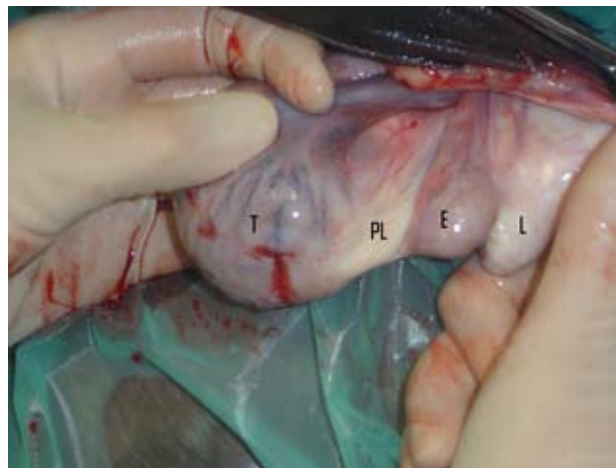#### SAMENVATTING

In deze casuïstiek wordt een torsie van de zaadstreng over 720 graden bij een twee jarige warmbloed hengst beschreven. De diagnose werd gesteld door middel van palpatie en een echografisch onderzoek van het scrotum. Vermits de hengst niet voor dekdienst in aanmerking kwam, werd er overgegaan tot een bilaterale orchidectomie. In het geval van een zaadstrengtorsie is niet alleen de ischemie nefast maar ook de laesies door reperfusie hebben invloed op de normale functionaliteit van de testikel. Verschillende antioxidantia, zoals allopurinol en melatonine, kunnen preventief aangewend worden in een poging om dergelijke letsels te minimaliseren.

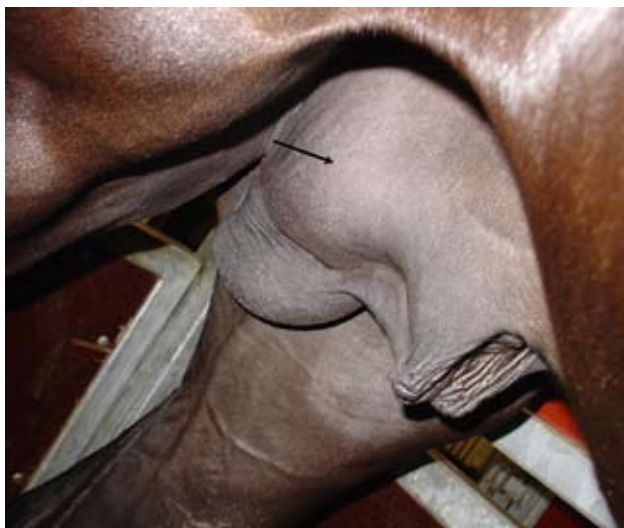#### INTRODUCTION

Torsion of the spermatic cord is sometimes incorrectly referred to as testicular torsion. Torsion of the spermatic cord occurs when the attached testis rotates on its vertical axis. A possible cause of torsion may be an elongated caudal ligament of the epididymis or an abnormally long proper ligament of the testis (Pascoe *et al.*, 1981) (Figure 1). Torsion of 180 degrees or less seems to cause no discomfort to stallions. Torsion of 360 degrees or more causes acute venous and arterial occlusion of testicular blood supply. This is accompanied by signs of acute pain, which may resemble acute colic pain, and enlargement of the affected testis and spermatic cord (Pascoe *et al.*, 1981). If the torsion is not reduced quickly, the testis and spermatic cord distal to the torsion become gangrenous (Schumacher and Varner, 1997). Spermatic cord torsion of an abdominally retained testis should be considered in the differential diagnosis of signs of abdominal pain in cryptorchid stallions (Hunt *et al.*, 1990). Torsion of the spermatic cord needs to be differentiated from inguinal herniation, orchitis, and epididymitis. These diseases produce similar signs

but can be excluded by palpation of the scrotal contents, examination of the vaginal rings per rectum and by the use of ultrasonography (U.S.). The treatment of torsion of 360° or more usually consists of



**Figure 1.** Anatomy of the normal testis and epididymis. 1) proper ligament (PL) of the testis (T), 2) ligament (L) of the tail of the epididymis (E).



**Figure 2.** The scrotum had an asymmetrical appearance due to retraction of the painful right testicle (arrow).

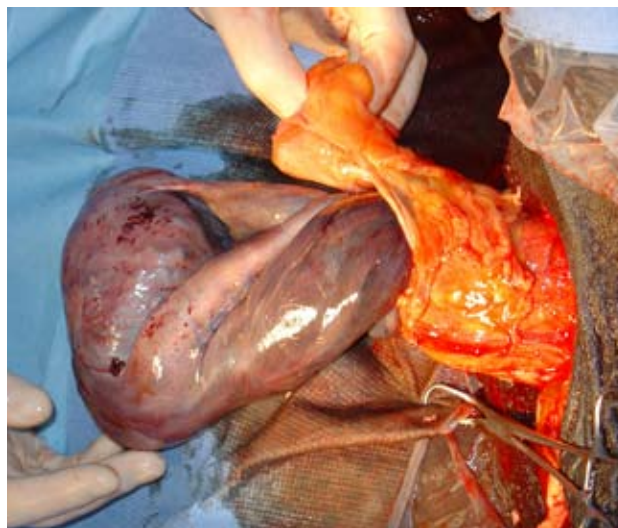
removal of the affected testis. In a very early stage it is possible to resolve the torsion and then attach the testicle in the scrotum (Schumacher and Varner, 1997; Knottenbelt, 2003).

#### CASE HISTORY AND CLINICAL FINDINGS

A 2.5-year-old Warm blood stallion was referred to the Veterinary Hospital of Ghent University with a 36-hour history of mild colic. Inspection of the scrotum revealed an asymmetrical appearance (Figure 2). On inspection, the right testicle was retracted towards the ventral abdomen and painful on palpation. The left testicle was normal and both caput and cauda epididymidis were correctly aligned. On the right side, although difficult to discern because of the tensed scrotum, it seemed like the cauda epididymidis was palpable on the cranial aspect of the scrotum. Examination per rectum of the internal inguinal rings revealed no abnormalities. Ultrasonography of the scrotum indicated increased fluid density throughout the right side of the scrotum. The testicular tissue on the right side was less echodense and more edematous. The palpably normal testis had a normal ultrasonographic appearance. The results of palpation of the extern genitalia, the examination per rectum and ultrasonography of the scrotum were indicative for torsion of the spermatic cord. The case was considered to be an emergency and the stallion was prepared for surgery.

#### SURGICAL PROCEDURE

Surgery was performed under general anesthesia with the horse in dorsal recumbency. A skin incision was made parallel and 1 cm lateral to the median raphe on the right side of the scrotum. The testicle, still contained within the common vaginal tunic, was freed from the scrotal fascia and forced ventrally out of the incision. The testicle was grasped and pulled ventrally with the left hand while the surgeon



**Figure 3.** During surgery, an enlarged, congested and hyperemic testicle was observed, due to 720 degree torsion of the spermatic cord.

stripped the fascia away from the testis and spermatic cord with the right hand. Subsequently an incision of approximately 4 cm was made through the cranial aspect of the common vaginal tunic and the testis was prolapsed. Exteriorization of the testicle and spermatic cord revealed 720 degree torsion on the spermatic cord, indicating that the findings on palpation of the scrotum were incorrect. The testicle was enlarged, congested and hyperemic (Figure 3). Because the testis, epididymis and testicular vasculature appeared devitalized, castration was performed. The spermatic cord and vaginal tunic were crushed and ligated as proximal as possible with synthetic absorbable suture material (Polyglycolic Acid USP 2, Dexon®). The testicle and associated structures distal to the ligature were removed. Some loose scrotal fascia was removed and the scrotal incision was left open to heal by second intention. Because future breeding potential was not important, the left testicle was also removed through a routine scrotal incision.

#### DISCUSSION

Stallions and dogs are possibly predisposed to torsion of the spermatic cord because of the horizontal position of the testicles within the scrotum (Threlfall *et al.*, 1990; Pinto *et al.*, 1998). Spermatic cord torsion has been reported in stallions and is thought to be associated with an elongated ligament of the tail of the epididymis and proper ligament of the testis (Horney and Barker, 1975; Pascoe *et al.*, 1981). Although cryptorchidism is common in stallions, acute torsion of intra-abdominal testes is rare. Torsion of the spermatic cord has been reported in two cryptorchid stallions with a seminoma of the undescended testis (Hunt *et al.*, 1990). Another report of intra-abdominal testicular torsion was not associated with neoplasia (Parker and Rakestraw, 1997). In dogs, testicular torsion is most common in intra-abdominal testes and is often associated with neoplasia (Pearson and Kelly, 1975).

In stallions, torsion of the spermatic cord can be chronic or intermittent, and clinical signs may not always be apparent (Threlfall *et al.*, 1990; Pinto *et al.*, 2001). According to Pascoe *et al.* (1981), torsion of 360° or more is accompanied by signs of acute pain. Contrary to the situation observed in stallions, torsion of the spermatic cord in dogs is usually an acute situation associated with signs of discomfort such as anorexia, lethargy, emesis and stiffness of gait (Pearson and Kelly, 1975).

The main pathology of testicular torsion is ischemia and reperfusion (IR) injury of the testis. The ischemia is caused by the twisting, and the reperfusion injury by the detorsion, of the spermatic cord. The reperfusion to the testicle following ischemia causes a further increase in tissue damage through an increase in peroxidation of lipids in the cell membrane. Nitric oxide (NO) is a free radical synthesized by a family of nitric oxide synthases (NOS). The up-regulation of iNOS (inducible nitric oxide synthases) leads to excessive NO production for prolonged periods of time and accounts for oxyradical-mediated damage in several organs. Nitric oxide is an important mediator of cell death, either through apoptosis or necrosis, depending on the intensity and duration of the injury. Germ cell apoptosis peaks at 24 hours after torsion and reperfusion, and declines after 48 hours. The first signs of germ cell necrosis appear at 24 hours after IR injury and gradually increase thereafter (Shiraishi *et al.*, 2001; Moon *et al.*, 2005). Several antioxidant agents such as allopurinol and melatonin have been used to prevent IR injury-induced tissue damage after experimental testicular torsion in rats. The results have shown that melatonin treatment prevents IR injury both biochemically and histopathologically, whereas allopurinol treatment prevents it only biochemically in experimental testicular torsion. Melatonin is a potent antioxidant agent that is more effective than allopurinol in preventing testicular IR injury (Akgur *et al.*, 1994; Ozturk *et al.*, 2003; Abasiyanik *et al.*, 2004). Intraperitoneal administration of resveratrol in rats may also protect the testis against injury associated with reperfusion (Uguralp *et al.*, 2005a, Uguralp *et al.*, 2005b).

Although torsion of the spermatic cord often has a detrimental effect on future fertility, the means of diagnosis and treatment in veterinary medicine remain rather limited compared to those available in human medicine. In human patients with testicular pain, an ultrasonographic study is performed, focusing on evaluation of the epididymis, testis and scrotal wall. The ultrasonographic appearance of torsion of the spermatic cord varies with the duration and degree of the rotation. Gray scale images are non-specific for torsion of the spermatic cord and often appear normal during the first hours after torsion. Adding a color Doppler US is an extremely useful technique in the evaluation of testicular perfusion. The high sensitivity of color Doppler US is based on the detection of a marked decrease or absence of intratesticular flow. Torsion is not an all-or-none phenomenon, as it may be complete, incomplete or transient. Patients with incomplete torsion have complete venous obstruction, but arterial flow is still detected. In these cases, color Doppler US may result in false-negative

interpretations. On the other hand, retrograde diastolic blood flow was detected in a case of 180° torsion of the spermatic cord (Pozor and McDonnell, 2004).

Primary torsion occurs in the spermatic cord and not in the testis. The finding of a rotated spermatic cord on ultrasound can be a highly reliable and direct sign for the diagnosis of torsion, and this is especially important when vascular flow is present within the affected testis on color Doppler US examination. Examination of the spermatic cord should therefore be added in the evaluation of the testis in patients with suspected torsion of the spermatic cord to enhance the sensitivity of the examination (Burks *et al.*, 1990; Arce, 2002; Dogra *et al.*, 2003; Muttarak and Lojanapivat, 2005).

Treatment of torsion in human patients consists of immediate exploration and fixation of the rotated testis (orchiopexy). An elongated caudal ligament of the epididymis and an abnormally long proper ligament of the testis are possible causes of torsion of the spermatic cord. These anatomic variations are likely to be bilateral and therefore the opposite testis should be fixed as well (Halland and Jonler, 2005). Threlfall *et al.* (1990) described a case of a stallion with left-sided torsion of the spermatic cord that underwent unilateral castration. Four years later, the stallion was referred to the hospital with a right-sided torsion. Even in cases in which surgically successful detorsion has occurred, the ipsilateral testis often becomes permanently dysfunctional. The reason for this loss of function in the potentially viable testis is often unclear (Turner and Brown, 1993).

Some investigators suggest that in cases of unilateral torsion, contralateral testicular damage and depressed fertility may occur due to the formation of anti-sperm antibodies (Merimsky *et al.*, 1984; Zanchetta *et al.*, 1984; Kosar *et al.* 1999). Other studies claim that unilateral torsion of the spermatic cord does not affect the contralateral testicle (Turner, 1985; Turner, 1987). A histological review of testicular biopsies of the contralateral testis revealed a high incidence of contralateral histological abnormalities. Their nature, however, suggests that they were present prior to the torsion. It is believed that some patients who suffer from torsion of the spermatic cord have congenital anomalies of the testicular parenchyma and the suspension system of both testicles (Laor *et al.*, 1990). Whether these anomalies are both congenital and hereditary has not yet been determined.

## REFERENCES

- Abasiyanik A., Dagdonderen L. (2004). Beneficial effects of melatonin compared with allopurinol in experimental testicular torsion. *Journal of Pediatric Surgery* 39, 1238-1241.
- Akgur F.M., Kilinc K., Aktug T., Olguner M. (1994). The effect of allopurinol pre-treatment before detorting testicular torsion. *Journal of Urology* 151, 1715-1717.
- Arce J.D., Cortés M., Vargas J.C. (2002). Sonographic diagnosis of acute spermatic cord torsion. *Pediatric Radiology* 32, 485-491.
- Burks D.D., Markey B.J., Burkhard T.K., Balsara Z.N., Haluszka M.M., Canning D.A. (1990). Suspected tes-

- testicular torsion and ischemia: evaluation with color Doppler sonography. *Radiology* 175, 815-821.
- Dogra V.S., Gottlieb R.H., Oka M., Rubens D.J. (2003). Sonography of the scrotum. *Radiology* 227, 18-36.
- Halland A., Jonler M. (2005). Testicular torsion after previous fixation of the testis. *Ugeskrift for Laeger* 167, 4476-4477.
- Horney F.D., Barker C.A. (1975). Torsion of the testicle in a standardbred. *Canadian Veterinary Journal* 16, 272-273.
- Hunt R.J., Hay W., Collatos C., Welles E. (1990). Testicular seminoma associated with torsion of the spermatic cord in two cryptorchid stallions. *Journal of the American Veterinary Medical Association* 197, 1484-1486.
- Kosar A., Kupeli B., Alcigir G., Ataoglu H., Sarica K., Kupeli S. (1999). Immunologic aspect of testicular torsion: detection of antisperm antibodies in contralateral testicle. *European Urology* 36, 640-644.
- Laor E., Fisch H., Tennenbaum S., Sesterhenn I., Mostofi K., Reid R.E. (1990). Unilateral testicular torsion: abnormal histological findings in the contralateral testis - cause or effect? *British Journal of Urology* 65, 520-523.
- Lopate C., Leblanc M., Knottenbelt D.C. (2003). The stallion. In: Knottenbelt D.C. (editor). *Equine Stud Farm Medicine and Surgery*. Edinburgh, WB Saunders Company 98-99.
- Merimsky E., Orni-Wasserlauf R., Yust I. (1984). Assessment of immunological mechanism in infertility of the rat after experimental testicular torsion. *Urological Research* 12, 179-182.
- Moon C., Ahn M., Kim S., Yasuzumi F., Shin T. (2005). Increased expression of both constitutive and inducible forms of nitric oxide synthase in the delayed phase of acute experimental testicular torsion. *Journal of Veterinary Medical Science* 67, 453-456.
- Muttarak M., Lojanapiwat B. (2005). The painful scrotum: an ultrasonographical approach to diagnosis. *Singapore Medical Journal* 46, 352-357.
- Ozturk A., Baltaci A.K., Mogulkoc R., Ozturk B. (2003). The effect of prophylactic melatonin administration on reperfusion damage in experimental testis ischemia-reperfusion. *Neuro Endocrinology Letters* 24, 170-172.
- Parker J.E., Rakestrew P.C. (1997). Intra-abdominal testicular torsion in a horse without signs of colic. *Journal of the American Veterinary Medical Association* 210, 375-377.
- Pascoe J.R., Ellenburg T.V., Culbertson M.R., Meagher D.M. (1981). Torsion of the spermatic cord in a horse. *Journal of the American Veterinary Medical Association* 178, 242-245.
- Pearson H., Kelly D.F. (1975). Testicular torsion in the dog: a review of 13 cases. *The Veterinary Record* 97, 200-204.
- Pinto C.R.F., Eilts B.E., Paccamonti D.L., Burba D.J. (1998). Theriogenology question of the month. *Journal of the American Veterinary Medical Association* 213, 205-206.
- Pinto C.R.F., Paccamonti D.L., Partington B. (2001). Theriogenology question of the month. *Journal of the American Veterinary Medical Association* 219, 1343-1345.
- Pozor M.A., McDonnell S.M. (2004). Color Doppler ultrasound evaluation of testicular blood flow in stallions. *Theriogenology* 61, 799-810.
- Schumacher J., Varner D.D. (1997). Surgical correction of abnormalities affecting the reproductive organs of stallions. In: Youngquist R.S. (editor). *Current Therapy in Large Animal Theriogenology*. Philadelphia, WB Saunders Company 24-36.
- Shiraishi K., Naito K., Yoshida K. (2001). Nitric oxide promotes germ cell necrosis in the delayed phase after experimental testicular torsion of rat. *Biology of Reproduction* 65, 514-521.
- Threlfall W.R., Carleton C.L., Robertson J., Rosol T., Gabel A. (1990). Recurrent torsion of the spermatic cord and scrotal testis in a stallion. *Journal of the American Veterinary Medical Association* 196, 1641-1643.
- Turner T.T. (1985). Acute experimental testicular torsion. No effect on the contralateral testis. *Journal of Andrology* 6, 65-72.
- Turner T.T. (1987). On unilateral testicular and epididymal torsion: no effect on the contralateral testis. *Journal of Urology* 138, 1285-1290.
- Turner T.T., Brown K.J. (1993). Spermatic cord torsion: loss of spermatogenesis despite return of blood flow. *Biology of Reproduction* 49, 401-407.
- Uguralp S., Mizrak B., Karabulut A.B. (2005a). Resveratrol reduces ischemia reperfusion injury after experimental testicular torsion. *European Journal of Pediatric Surgery* 15, 114-119.
- Uguralp S., Usta U., Mizrak B. (2005b). Resveratrol may reduce apoptosis of rat testicular germ cells after experimental testicular torsion. *European Journal of Pediatric Surgery* 15, 333-336.
- Zanchetta R., Mastrogiacomo I., Graziotti P., Foresta C., Betterle C. (1984). Autoantibodies against Leydig cells in patients after spermatic cord torsion. *Clinical Experimental Immunology* 55, 49-57.