

VERRUCOUS VALVULAR ENDOCARDITIS DUE TO *PASTEURELLA MULTOCIDA* IN A CAT

Verruceuze valvulaire endocarditis ten gevolge van Pasteurella multocida bij een kat

H. De Bosschere¹, S. Roels², E. Vanopdenbosch²

¹Medisch Labo Bruyland – Meditest, Meiweg 1, BE-8500 Kortrijk, Belgium

²Veterinary Agrochemical Research Centre (VAR), Department of Biocontrol,
Groeselenberg 99, BE-1180 Brussels (Ukkel), Belgium

hendrik.de.bosschere@bruyland.be

ABSTRACT

A case of verrucous endocarditis of the mitral valve was diagnosed in a domestic tomcat. The animal appeared to have died of cardiac failure and/or septicemic shock as septic emboli were present in multiple organs such as the liver and kidneys. The mitral valve was covered with multiple yellow/grey cauliflower-like nodules. Culture of these nodules revealed *Pasteurella multocida* after isolation and identification.

SAMENVATTING

Dit is de beschrijving van een verruceuze endocarditis van de mitralisklep bij een mannelijke huiskat. Het dier is waarschijnlijk gestorven aan hartfalen en/of septikemische shock. In meerdere organen, zoals de lever en de nieren, werd septische embolie aangetroffen. De mitralisklep was bedekt met witgrijze, bloemkoolachtige nodulen. Uit deze nodulen werd na cultuur *Pasteurella multocida* geïdentificeerd.

INTRODUCTION

Endocarditis is the inflammation of one of the cardiac valves. The aortic and mitral valves are the most commonly affected in dogs, horses, and cats (The Merck Veterinary Manual, 2006), while the tricuspid valve is rarely affected, and endocarditis of the pulmonic valve is extremely uncommon. In cattle, however, the tricuspid valve is the most commonly affected cardiac valve (The Merck Veterinary Manual, 2006). In cats, bacterial endocarditis is a rare and life-threatening disorder (De Jonghe *et al.*, 1998, Malik *et al.*, 1999, The Merck Veterinary Manual, 2006).

Endothelial damage is assumed to be present before infective endocarditis can develop. When the endothelium is partially eroded, exposing the underlying collagen, platelets can adhere and produce a thrombus. Next, blood borne bacteria may become trapped in this thrombic lattice, resulting in a localized infection with progressive destruction of the valve and consequent valvular insufficiency (Robinson and Grant Maxie, 1993; The Merck

Veterinary Manual, 2006). Many bacterial species are capable of causing valvular endocarditis, but the most frequently isolated agents are *Staphylococcus aureus* (Yamaguchi *et al.*, 1992), Streptococci, Staphylococci, *Pseudomonas aeruginosa*, *Escherichia coli* (Shouse and Meier, 1956) and *Bartonella henselae* (Chomel *et al.*, 2003).

The present paper describes a case of a domestic tomcat with verrucous endocarditis of the mitral valve caused by *Pasteurella multocida*. This is, to the author's knowledge, the first report of valvular endocarditis in a cat induced by *Pasteurella multocida*.

CASE REPORT

A 6-year-old intact male, domestic short haired cat was found dead and presented for autopsy. According to the owner, the cat did not show any symptoms prior to its death. There was also no history of previous illnesses. The cat was vaccinated for feline panleucopenia and

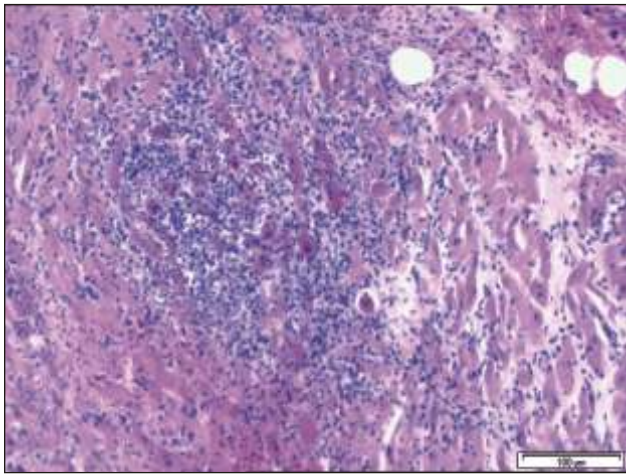


Figure 1. Microphotograph of a mitral valve leaflet showing a thickened appearance due to fibrosis (HE staining).

rhinitis. However, the cat lived predominantly outdoors, making close monitoring of its behavior very difficult. On autopsy, the animal was dehydrated. Multiple petechiae were present in multiple organs, including the lungs, intestine, liver, kidneys and multiple lymph nodes. The pericardium was filled with 5 ml of sero-sanguinous fluid and the epicardium showed multiple large hemorrhages and fibrin deposits. There was moderate dilation of the left ventricle, and myocardial hypertrophy affecting the left ventricle. The endocardium of the left atrium showed multiple jet-lesions and fibrosis above the mitral valve. Yellow to grey cauliflower-like nodules were present on the mitral valve (diameter of approximately 3 mm). Hemorrhages were also present in the truncus pulmonalis.

Histopathologically, the mitral valve leaflets of the heart were thickened due to fibrosis (Figure 1) and locally covered with bacterial colonies. There was a marked presence of necrotic tissue and a severe mixed inflammatory reaction, with hemorrhages and fibrosis in the tissue adjacent to the valve. The rest of the heart showed a severe mixed perivasculitis and a diffuse infiltration of inflammatory cells (especially neutrophils) in the myocardium, adipose and fibrous tissues. Multiple micro-abscesses, hemorrhages, degeneration of myocardial fibers and necrotic foci were also noted (Figure 2). The superficial lymph nodes showed congestion and hemorrhages, with marked activation of the lymphoid tissue and micro-abscesses. Sections of the liver demonstrated moderate perivasculitis, with scattered infiltration predominantly of neutrophils between the sinusoids and multiple micro-abscesses. Histological examination of the kidneys revealed hemorrhages, fibrosis, degeneration of glomeruli and tubules, generalized glomerulonephritis and abscessation of glomeruli.

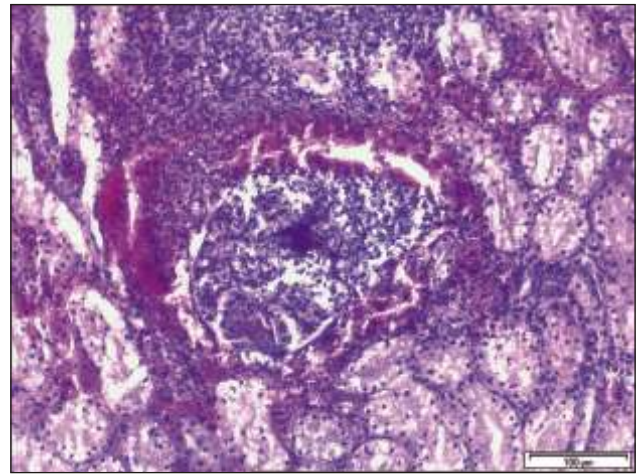


Figure 2. Microphotograph of myocardium presenting a myocardial abscess and interstitial myocarditis (HE staining).

Direct immunofluorescence of the spleen for feline immunodeficiency virus (FIV) and feline leukemia virus (FeLV) were negative. Bacteriology of the mitral valve and kidney, using a blood agar plate, revealed small, mucoid colonies, which appeared to be Gram negative rods after Gram staining. Identification of these colonies using the BioMerieux Vitek 2 Lab Report system revealed *Pasteurella multocida*.

A diagnosis of verrucous valvular endocarditis due to *Pasteurella multocida* with septic emboli in kidneys and liver was suggested. This probably resulted in heart failure and/or septicemic shock, which resulted in death.

DISCUSSION

Pasteurella multocida is commonly found in dogs and cats. Pasteurellae are found in the respiratory tract, where they are associated with rhinitis, pneumonia and bronchitis. They are also noted in the genital tract (primarily the vagina) and in the mouth (especially in gingivitis in cats) (McCandlish and Taylor, 1998). Because dogs and cats harbor these organisms in their mouths as commensals, humans and other animals are frequently infected by bites. A wide variety of infections have been reported in humans, including sinusitis, pneumonia, peritonitis, urinary tract infection, endocarditis, otitis, meningitis, abscesses, cellulites, tonsillitis, appendicitis, bacteremia and septicemia (Carter *et al.*, 1995; Fajfar-Whetstone *et al.*, 1995).

When bacteria become detached from the infected mitral valves, they enter the circulation and may colonize other organs. Therefore, a wide spectrum of clinical signs can be observed with infective endocarditis, including primary cardiovascular effects, or signs related to the nervous system, the gastro-intestinal tract, the urogenital system or the joints (hematuria and pyuria, or shifting leg lameness) (The Merck Veterinary Manual, 2006). In

almost all cases, a chronic, intermittent fever, weight loss and lethargy are present. In most cases, a cardiac murmur is noted. The exact type depends on the valve involved. The murmur observed in mitral valve endocarditis is similar to that caused by degenerative valve disease, i.e. a low- to high-grade systolic murmur (The Merck Veterinary Manual, 2006). The frequency with which clinical signs are observed is dependent on the husbandry conditions under which the animal is kept. In the present case, no clinical symptoms were observed as the animal was not monitored very well due to its free-ranging lifestyle.

The specific mechanism of the pathogenesis of *Pasteurella* has been described as follows: *Pasteurella* species are believed to adhere to the mucosal epithelium of the upper respiratory tract, and especially of the tonsils. The adherence in some of the cases is mediated by fimbriae, which is especially noted in the toxigenic strains (Murray *et al.*, 1999). The different *Pasteurella* species also produce several virulence factors and toxins (e.g. leukotoxin). They therefore impair cellular response and stimulate inflammatory response. In addition, most virulent strains of *Pasteurella* produce polysaccharide capsules that are antiphagocytic and inhibit intracellular killing by neutrophils (Murray *et al.*, 1999).

On hematology and biochemistry, a neutrophilic leukocytosis is often observed. The presence of band neutrophils is linked with an active infection, while monocytosis is associated with a chronic infection. In chronic cases, anemia is frequently present. Abnormalities observed in serum biochemistry reflect organ involvement secondary to infective emboli released into the circulation. They may include increases in liver enzymes, uremia, and creatinine. Patients developing immune complex glomerulonephritis may show significant urinary protein loss and hypoalbuminemia (The Merck Veterinary Manual, 2006).

Enlargement of the cardiac chamber, depending on the location and degree of insufficiency of the valve involved can be seen on radiographs. In mitral valve endocarditis, the left atrial and left ventricular dilatation may be affected. Echocardiographically, the affected valve is easily detected, because the area involved is hyperechoic (=bright) and thickened. Insufficiency of the valve can be confirmed using Doppler echocardiography, while chamber enlargement on the side of the affected valve is expected when significant insufficiency is present (The Merck Veterinary Manual, 2006). With electrocardiography it is possible to demonstrate atrial and ventricular premature complexes, as well as arrhythmias such as atrial fibrillation or conduction disturbances. Increased height of the R waves is suggestive of left ventricular enlargement, while increased width of the P wave is suggestive of left atrial

enlargement (The Merck Veterinary Manual, 2006). Unfortunately, none of these examinations could be done in the present case.

The lesions of bacterial endocarditis are usually observed as large vegetative growths on the affected valves (Robbinson and Grant Maxie, 1993). It is unusual to find a primary lesion or source of infection (De Jonghe *et al.*, 1998), although endocarditis may occur following infections at various sites including the skin (bite wound), bone, lung, urogenital tract, prostate, mammary gland, oropharynx, intestinal and perineal tissues (De Jonghe *et al.*, 1998). No specific infectious focus was detected in this case. Grossly the vegetations are yellow-red or yellow-grey in appearance. Endocarditis of the atrioventricular valves tends to spread along the chordae tendinae, causing some of them to rupture. This was not noticed in the present case. Cats infected with FeLV or FIV, or cats receiving corticosteroids (i.e. immunocompromized animals) are believe to be at greater risk (De Jonghe *et al.*, 1998), though this tomcat tested negative for both viruses. Portions of the vegetations may become detached and carried as emboli, to become impacted in the vessels of other organs, such as the liver and kidneys in the present case, resulting in septic or aseptic infarcts and embolic glomerulonephritis, and in the myocardium as myocardial abscesses or interstitial myocarditis, as was also observed in the present case.

Therapy should be focused on controlling the clinical signs of heart failure, resolving arrhythmias, sterilizing the lesion, and eliminating the spread of infection. If the aortic valve is significantly involved, the heart failure may be extreme and intractable, resulting in a very poor prognosis. The prognosis is much more favorable when the infection is mild and limited to one of the atrioventricular valves. The treatment of heart failure includes the use of diuretics (e.g. furosemide), ACE inhibitors, and digoxin (if myocardial failure or supraventricular arrhythmias are present). Initially, the use of parenteral broad-spectrum antibiotics is recommended for a period of 1 to 2 weeks, followed by oral administration of antibiotics for another 6 to 8 weeks (The Merck Veterinary Manual, 2006).

In conclusion, infective endocarditis usually has a poor clinical course. Therefore the prophylactic use of a broad-spectrum antibiotic is recommended for animals with a predisposing cardiac disease (e.g. subaortic stenosis, patent ductus arteriosus, ventricular septal defect, cyanotic congenital heart disease) that are to be subjected to procedures having a potential to cause bacteremia (e.g. dental scaling, tooth extractions) (The Merck Veterinary Manual, 2006). *Pasteurella multocida* should be added to the list of potential etiologies of endocarditis in cats.

ACKNOWLEDGEMENTS

The authors would like to thank the staff of the Department of Biocontrol (CODA) and Medisch Labo Bruyland for their technical assistance.

REFERENCES

- Carter G. R., Chengappa M. M., Roberts A. W. (1995). *Pasteurella multocida*. In: Carter G.R., et al. (eds). *Essentials of Veterinary Microbiology*. 5th edition, Williams & Wilkins, London, pp. 173 – 176.
- Chomel B. B., Wey A. C., Kasten R. W., Stacy B. A., Labelle P. (2003). Fatal case of endocarditis associated with *Bartonella henselae* type I infection in a domestic cat. *Journal of Clinical Microbiology* 41, 5337 – 5339.
- De Jonghe S., Ducatelle R., Devriese L. A., Haesebrouck F., Roels S. (1998). Verrucous endocarditis due to *Escherichia coli* in a Persian cat. *The Veterinary Record* 143, 305 – 307.
- Fajfar-Whetstone C. J. T., Coleman L., Biggs D. R., Fox B. C. (1995). *Pasteurella multocida* septicemia and subsequent *Pasteurella dagmatis* septicemia in a diabetic patient. *Journal of Clinical Microbiology* 33, 202 – 204.
- Malik R., Bars V. R., Church D. B., Zahn A., Allan G. S., Martin P., Wigney D. I., Love D. N. (1999). Vegetative endocarditis in six cats. *Journal of Feline Medical Surgery* 1, 171 – 180.
- McCandlish I. A. P., Taylor D. J. (1998). Microbiological testing. In: Davidson M., Else R., Lumsden J. (eds.). *Manual of Small Animal Clinical Pathology*. British Small Animal Veterinary Association, Cheltenham, U. K., pp. 105.
- Murray P. R., Tenover F. C., Tenover F. C., Tenover F. C., Tenover R.H. (1999). In: Murray P.R., et al. (eds.). *Manual of Clinical Microbiology*. 7th edition, ASM Press, Washington, D.C.
- Robinson W. F., Grant Maxie M. (1993). The Cardiovascular System. In: Jubb KVF, Kennedy PC, Palmer N (eds). *Pathology of Domestic Animals*, Vol. 3. Academic Press, San Diego, USA, pp. 24 – 25.
- Shouse C., Meier H. (1956). Acute vegetative endocarditis in the dog and cat. *Journal of the American Veterinary Medical Association* 129, 278 – 289.
- The Merck Veterinary Manual, Merck – Merial (2006). Infective endocarditis. <http://www.merckvetmanual.com/mvm/index.jsp>, last consulted on 6 September 2006.
- Yamaguchi R. A., Pipers F. S., Gamble D. A. (1983). Echocardiographic evaluation of a cat with bacterial vegetative endocarditis. *Journal of the American Veterinary Medical Association* 183, 118 – 120.

Uit het verleden

DE TWEE KATTEN VAN HET PANDJESHUIS (1693)

In vroegere tijden apprecieerde (en accepteerde) men katten vooral als muizenjagers. Soms had men er zelfs iets voor over. Bewijzen daarvan zijn uiterst zeldzaam, maar hier toch eentje uit de rekeningen van de Gentse ‘Berg van Barmhartigheid’, een grote officiële stedelijke instelling, gehuisvest in een prachtig gebouw aan de Abrahamstraat. In dit pandjeshuis konden mensen in nood geld lenen tegen het inbrengen van een pand. Die panden waren niet enkel juwelen, maar niet zelden ook kledingstukken die het liefst ongeschonden moesten bewaard worden en katten waren daarvoor blijkbaar een gewaardeerde hulp. Zo noteerde de betaalmeeester in 1693 een kleine som voor de aankoop van voer voor de twee katten die het pandjeshuis vrijwaarden, veronderstellen we, van harige knagende bestjes.

Uit : Charles, L. et al. De Berg van Barmhartigheid in Gent, Gent, 2003, p. 52.

Luc Devriese