

***LISTERIA MONOCYTOGENES* ASSOCIATED MYOCARDIAL PERFORATION IN A BEARDED DRAGON (*POGONA VITTICEPS*)**

Myocardperforatie geassocieerd met Listeria monocytogenes bij een baardagame (Pogona vitticeps)

D. Vancraeynest, F. Pasmans, E. De Graef, K. Hermans, A. Decostere

Department of Pathology, Bacteriology and Avian Diseases
Faculty of Veterinary Medicine, Ghent University
Salisburylaan 133, B-9820 Merelbeke, Belgium
Dieter.vancraeynest@Ugent.be

ABSTRACT

This paper describes the clinical symptoms and the macroscopic lesions associated with myocardial perforation in a bearded dragon (*Pogona vitticeps*). Bacteriological examination of the myocardium yielded a pure culture of *Listeria monocytogenes*. To the best of our knowledge, this is the first report of an *L. monocytogenes* infection associated with cardiac disease in reptiles.

SAMENVATTING

Dit artikel beschrijft de klinische symptomen en de macroscopische letsels bij een baardagame (*Pogona vitticeps*) met een myocardperforatie. Bacteriologisch onderzoek van het myocard resulteerde in een reïncultuur van *Listeria monocytogenes*. Voor zover bekend is dit de eerste beschrijving van een *L. monocytogenes* infectie bij reptielen die geassocieerd is met hartfalen.

INTRODUCTION

Listeria monocytogenes infections occur worldwide in a variety of animals and man (Low and Donachie, 1997). This bacterium was first described from an epidemic disease of rabbits and guinea pigs in a laboratory animal breeding unit (Murray *et al.*, 1926). Today, listeriosis is of major veterinary importance in cattle and sheep, where it is associated with silage feeding (Low and Donachie, 1997). *L. monocytogenes* has been found in feces samples of various healthy tortoises and snakes (Weber *et al.*, 1993). However, it has been associated only very rarely with overt disease in reptiles.

CASE REPORT

A female, one-year-old bearded dragon (*Pogona vitticeps*) of 550 grams was presented because of anorexia and what the owners described as "protruding eyes". It had been housed together with another bearded dragon and the animals lived together amicably. Housing conditions and food quality were appropriate, but the animals

were overfed. The sick animal had been off feed for a few days.

The animal was lethargic and obese. It suffered from severe edema of the peri-orbital tissues and the throat region (Figure 1). Frequency of respiration was decreased and the animal suffered from inspiratory dyspnea. In view of the poor general condition of the animal, it was hospitalized. In order to initiate an appropriate therapy, limited blood biochemistry was performed. Liver and kidney function and blood protein levels were evaluated. Calcium, total protein and albumin values were normal, but uric acid, phosphorus, AST and ALT were elevated (Table 1), indicating renal and hepatic dysfunction.

The animal died 12 hours after presentation. Necropsy was performed and revealed severe subcutaneous edema, especially in the throat region. The animal had a very large fat pad and an enlarged liver with fatty appearance. The body cavity was filled with a massive amount of fluid. The most striking pathological finding was a severe accumulation of caseous pus in the pericardial sac (Figure 2). Further dissection revealed a defect in the myocardium, resulting in a connection between the ventricle and the



Figure 1. Inspiratory dyspnea and peri-orbital edema.

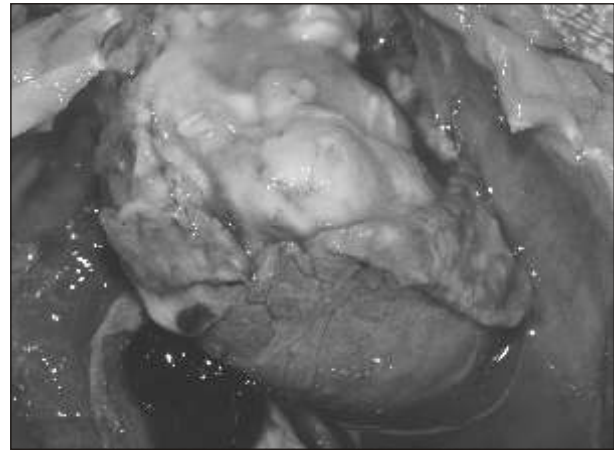


Figure 2. Caseous pus in the pericardial sac, which was incised.

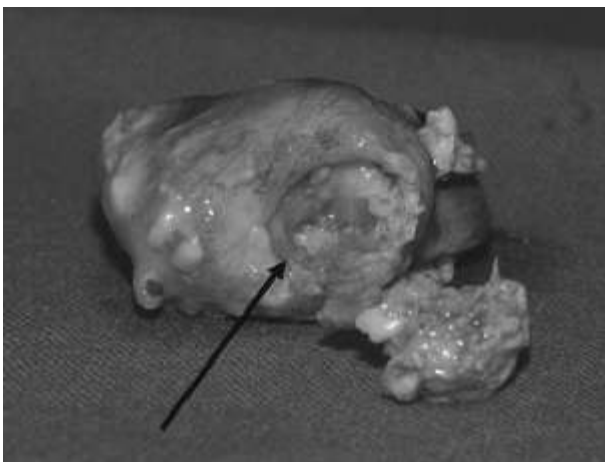


Figure 3. The heart after removal. The arrow indicates the myocardial defect. The plug that was blocking it, was removed and is lying next to the heart.

pericardium. The ventricle defect was filled with a firm caseous plug (Figure 3). There were no gross signs of gout and the kidneys had a normal macroscopic appearance.

Samples were sent for bacteriological culture. Overnight incubation resulted in a pure culture of *Listeria monocytogenes*, which was confirmed by tDNA-PCR as described by Baele *et al.* (2000).

DISCUSSION

L. monocytogenes is distributed worldwide and is capable of infecting a vast amount of mammalian, avian, amphibian and fish species (Posfay-Barbe and Wald, 2004). *L. monocytogenes* has also been isolated from an

Table 1. Biochemical values.

Parameter	Value	Reference value ⁽¹⁾	Unit
Calcium	17.52	16.2 ± 11.2	mg/dl
Phosphorus	9.83⁽²⁾	5.6 ± 2.5	mg/dl
Uric acid	26.7	4.4 ± 2.6	mg/dl
Total protein	4.7	5.0 ± 1.4	g/dl
Albumin	2.2	2.6 ± 0.8	g/dl
AST	119	27 ± 23	U/l
ALT	30	11 ± 5	U/l

(1) Source: Cranfield *et al.*, 1996.

(2) Data represented in bold are elevated.

abscess in the lizard *Tupinambis rufescens* (Mayer and Frank, 1974). However, other reports of *L. monocytogenes* causing disease in reptiles are scarce.

Weber *et al.* (1993) already demonstrated a prevalence of 11.8% of *Listeria* sp. (predominantly *L. monocytogenes*) in fecal samples of several healthy reptile and amphibian species. In lizards, only *L. ivanovii* and *L. welshimeri* were isolated, but one can assume that these animals can also carry *L. monocytogenes* in the gut. As *Listeria* sp. have zoonotic potential and because lizards are also infamous *Salmonella* carriers (Pasmans *et al.*, 2005), basic hygiene should be applied in reptile husbandry.

The pathogenesis in this particular case is unclear. However, one probable hypothesis is that the animal carried *L. monocytogenes* in the gut and that the bacterium penetrated the mucosal barrier, leading to septicemia and endocarditis, which eventually resulted in myocardial perforation. Although the animal was somewhat obese, the management of this bearded dragon was good and there were no signs of other disease processes. Therefore, no clear underlying causes for the infection could be identified. Thus it is unknown whether or not the bacterium was the primary pathogen.

Cardiac diseases, especially those of infectious origin, are rare in reptiles. A literature review by Girling and Hynes (2004) revealed only six reported cases of cardiac-associated disease of bacterial origin in non-crocodilian reptiles. To the best of our knowledge, this is the first report of a *L. monocytogenes* infection associated with cardiac disease in reptiles. Moreover, it is the first description of an infectious disease associated with myocardial perforation.

REFERENCES

- Baele M., Baele P., Vanechoutte M., Storms V., Butaye P., Devriese L.A., Verschraegen G., Gillis M., Haesebrouck F. (2000). Application of tRNA intergenic spacer PCR for identification of *Enterococcus* species. *Journal of Clinical Microbiology* 38, 4201-4207.
- Cranfield M., Graczyk T., Lodwick L. (1996). In: J.W. Carpenter (ed.). *Exotic Animal Formulary*. 3rd ed. St. Louis, Elsevier Inc. p. 100.
- Girling S.J., Hynes B. (2004). Cardiovascular and haemopoietic systems. In: S.J. Girling, P. Raiti (eds.) *British Small Animal Veterinary Association (BSAVA) Manual of Reptiles*. 2nd edition. Quedgeley, British Small Animal Veterinary Association, pp. 243-260.
- Low J.C., Donachie W. (1997). A review of *Listeria monocytogenes* and Listeriosis. *The Veterinary Journal* 153, 9-29.
- Mayer H., Frank W. (1974). Bakteriologische Untersuchungen bei Reptilien und Amphibien. *Zentralblatt für Bakteriologie, Mikrobiologie und Hygiene I Abteilung Originale A* 229, 470-481.
- Murray E.G.D., Webb R.A., Swann M.B.R. (1926). A disease of rabbits characterised by a large mononuclear leucocytosis caused by a hitherto undescribed bacillus *Bacillus monocytogenes*. *Journal of Pathology and Bacteriology* 29, 407-439.
- Pasmans F., Martel A., Boyen F., Vandekerchove D., Wybo I., Van Immerseel F., Heyndrickx M., Collard J.-M., Ducatelle R., Haesebrouck F. (2005). Characterization of *Salmonella* isolates from captive lizards. *Veterinary Microbiology* 110, 285-291.
- Posfay-Barbe K.M., Wald E.R. (2004). Listeriosis. *Pediatrics in Review* 25, 151-159.
- Weber A., Prell A., Potel J., Schäfer R. (1993). Vorkommen von *Listeria monocytogenes* bei Schlangen, Schildkröten, Echsen und Amphibien in der Heimtierhaltung. *Berliner und Münchener Tierärztliche Wochenschrift* 106, 293-295.