

## DISSEMINATED CRYPTOCOCCOSIS IN A CAT IN A MODERATE CLIMATE REGION

*Gegeneraliseerde cryptococcose bij een kat in een gematigde klimaatzone*

G. Junius, E. Schrauwen

DAP Plantijn, Bosduifstraat 18/20, 2018 Antwerpen, België

### ABSTRACT

**Cryptococcosis is a subacute to chronic fungal disease that can occur in several species. This disease is usually seen in warm climates, and only a few cases have been described in moderate climate regions. The disease can remain localized in the nose and sinuses, but often extends to lungs, brain, and skin. In this report, the first case of disseminated cryptococcosis in a cat in Belgium is described.**

### SAMENVATTING

Cryptococcosis is een subacute tot chronische schimmelaandoening die bij verscheidene diersoorten kan voorkomen. Deze ziekte-entiteit wordt meestal gezien in warme klimaatzones en wordt slechts sporadisch beschreven in gematigde klimaatgebieden. De aandoening kan gelokaliseerd voorkomen in neus en sinussen maar uitzaaiingen naar longen, hersenen en huid zijn mogelijk. In dit rapport wordt voor de eerste maal een geval van gedissemineerde cryptococcose bij een kat beschreven in België.

### INTRODUCTION

Cryptococcosis is a subacute to chronic, frequently fatal, fungal disease of dogs, cats, horses, cattle, sheep, goats, koalas and other animals. The cause is *Cryptococcus neoformans*, a soil-borne and yeast-like fungus. The agent is capable of multiplying to large numbers in the feces of pigeons and other birds, where it can remain viable for months. Although its distribution is worldwide, cryptococcosis mostly occurs in warm regions such as Australia, Hawaii, New Zealand, Papua New Guinea, and the southern United States (Gionfriddo, 2000). However, a few cases in more moderate climates have been described (Austria, the United Kingdom, The Netherlands, Canada, Japan) (Kohler *et al.*, 1976; Tjalsma, 1997; Gionfriddo, 2000).

Cryptococcosis is seen more frequently in cats than in dogs. The mode of infection is believed to be through inhalation of spores. The disease is manifested most commonly by lesions in nasal and frontal sinuses, particularly in cats, which can extend to the meninges, brain and lungs. Characteristic tumor-like granulomatous lesions can also be found in the skin

and subcutis (Medleau, 1990). In the disseminated disease, granulomas develop in various tissues and organs, including the central nervous system (CNS), and in the absence of treatment it usually terminates fatally. Clinical signs will depend on the stage of the disease. They include sneezing, coughing, nasal and ocular discharge, dilated fixed pupils, and, in the case of CNS involvement, ataxia, circling, blindness and locomotor dysfunction. Diagnosis is based on the demonstration of the typical yeast-like organisms in nasal and skin exudates, cerebrospinal fluid or tissue aspirates.

### CASE DESCRIPTION

A five-year-old male castrated domestic shorthair weighing 6 kg was presented because of a six-week history of respiratory disease with sneezing, purulent nasal discharge, ocular discharge and open mouth breathing. The animal had been treated with amoxicillin + clavulanic acid (Synulox; Pfizer) for two weeks, without effect. Clinical examination showed purulent nasal discharge, nasal stridor, ocular dis-

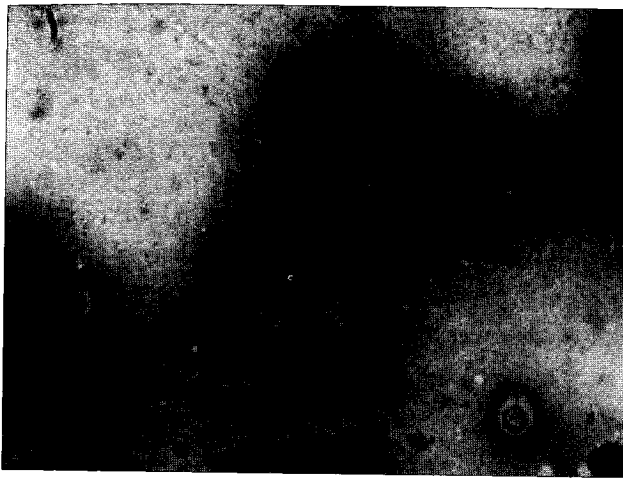


Fig. 1. Cytology of the nasal mass lesion, colored with Diff-Quick. The *Cryptococcus* organisms are round to oval basophilic structures, surrounded by a clear halo.

charge, open mouth breathing and enlarged mandibular lymph nodes. No other abnormalities were found, and thorax auscultation was normal.

Blood analysis revealed increased leucocytes ( $19.8$ , normal value:  $5$  to  $15 \times 10^9/l$ ) without a left shift, increased eosinophils ( $3660$ , normal value: less than  $800 \times 10^6/l$ ), and increased monocytes ( $850$ , normal value: less than  $550 \times 10^6/l$ ). The thrombocyte count, hematocrit, urea, creatinin, total protein, gamma-GT and bilirubin were normal. AST and ALT were elevated ( $96$  and  $130$ , respectively, with normal values less than  $46$  and  $43 U/l$ ). Serum protein electrophoresis showed an increase in gamma globulins ( $32.5$ , normal value  $10.8$  to  $24.6\%$ ). FIV and FeLV testing was negative. Cytological examination of the swollen mandibular lymph nodes revealed many eosinophils. Rhinoscopy was performed, and a swelling of the conchae was found, as well as a mass lesion in the left nasal cavity. Specimens of this lesion were obtained for cytology, histology and culture. Cytological examination of a stained specimen (Diff Quick) of the nasal mass lesion showed abundant *Cryptococcus*-like organisms (see Fig 1), and this finding was confirmed with histology and culture. Histology showed an eroded epithelium, with a dense inflammatory infiltrate in the connective tissue, consisting of many lymphocytes, plasma cells and histiocytes, but no eosinophils. Several cryptococcal organisms were present in this infiltrate. Bacteriological and mycological culture was performed on Tryptic Soy Agar with 5% horse blood, as well as on Sabouraud Gentamicin Chloramphenicol agar. The yeast was identified as *Cryptococcus neoformans* with the ID 32 C system (bio-Mérieux, Lyon).

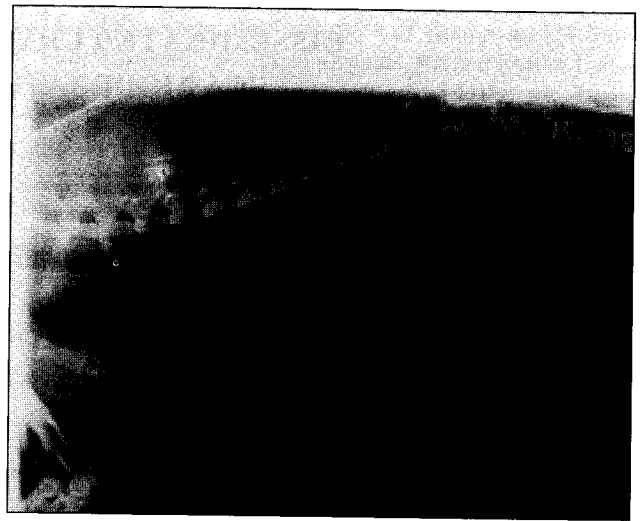

Fig. 2. A lateral radiograph of the thorax demonstrating a diffuse interstitial and peribronchial pattern.

A radiograph of the thorax was taken and showed pulmonary pathology (see Fig 2). Nasal radiography was not performed. No signs of eye or central nervous system involvement were present.

The cat was treated with fluconazole 25 mg once a day, and started to improve after three weeks. This treatment was given for two months, and then discontinued by the owner. One week later signs started to recur. Treatment was reinstated at a double dose (25 mg twice daily), but the cat was difficult to treat and the owner was not able to administer the full dose continuously. When the medication was not given for a few days, ocular discharge recurred, which forced the owner to continue treatment permanently. Clinical examination of the cat six months after diagnosis revealed no abnormalities, but on control radiographs similar pulmonary pathology was still present.

## DISCUSSION

Cryptococcosis is a very rare disease in our region, but should be considered in the differential diagnosis of a cat with chronic nasal disease. Diagnosis is usually easy using nasal flush cytology. Other treatment protocols could also have been used: amphotericin B and flucytosine, as well as itraconazole and ketoconazole, although ketoconazole appears to be less well tolerated (Gionfriddo, 2000). Fluconazole is well tolerated by cats, and a dose of up to 50 mg per cat twice daily can be used when needed (Malik *et al.*, 1992). It is effective for treating the disseminated form as it penetrates well into the brain, eye, lung, and urinary tract.

The observed systemic and lymph node eosinophilia has not been described previously in cryptococcosis in cats, and its significance is unclear.

#### ACKNOWLEDGEMENT

Dr. I. Putcuyps is kindly acknowledged for the interpretation of the thoracic radiographs.

#### REFERENCES

- Gionfriddo J.R. (2000). Feline systemic fungal infections. *Veterinary Clinics North America: Small Animal Practice* 30, 1029-1050.
- Kohler H., Gialamas J., Kuttin E.S. (1976). Cryptococcosis in a cat in Austria. *Deutsche Tierärztliche Wochenschrift* 83, 492-495.
- Malik R., Wigney D.I., Muir D.B., Gregory D.J., Love D.N. (1992) Cryptococcosis in cats: clinical and mycological assessment of 29 cases and evaluation of treatment using orally administered fluconazole. *Journal of Medical and Veterinary Mycology* 30, 133-144.
- Medleau L. (1990) Recently described feline dermatosis. *Veterinary Clinics North America: Small Animal Practice* 20, 1615-1632.
- Tjalsma E.J. (1997) Two cases of cryptococcosis in cats. *Tijdschrift voor Diergeneeskunde* 122, 128-132.